

Dental Glossary

alveolus: a socket in the jawbone that the root of a tooth is anchored to through the periodontal ligament

apex: the bottom point of a tooth's root

bicuspid: located behind the canines

The bicuspid is flat with prominent cusps that grind and mash food. Adults generally have eight bicuspid.

canines: located on either side of the incisors

The name comes from their similarity to dogs' fangs. Adults have four canines. They are used to tear food.

cementum: is the outer layer of the tooth below the gums

Like dentin, cementum is similar to bone and attaches the tooth to the jawbone.

crown: the portion of the tooth that is visible above the gum line

cusps: ridges on top of the crown that are used for grinding and chewing

deciduous teeth: also known as baby teeth, or milk teeth

These are the first set of teeth that human beings have.

dentin: is the layer beneath a tooth's enamel

Similar to bone, but stronger, dentin is a hard, mineral material that protects the pulp in the center of the tooth.

enamel: forms the outer layer of the tooth and protects the tooth from bacteria and temperature change

Enamel is the hardest substance in the human body.

incisors: located at the front of the mouth

Adults have eight incisors. These teeth have a straight, sharp edges and are used to cut food.

molars: located behind the bicuspid

Most adults have twelve molars; they are used for the most forceful chewing. There are three kinds of molars: first, second, and third molars. Third molars are also known as wisdom teeth.

periodontal ligament: attaches the cementum of a tooth to the alveolus

permanent teeth: the 32 teeth that replace baby teeth

pulp: the center of the tooth

This area consists of blood vessels that bring oxygen and nutrients to the tooth, as well as nerves that signal pain and temperature to the brain.

root: the portion of the tooth below the gum line

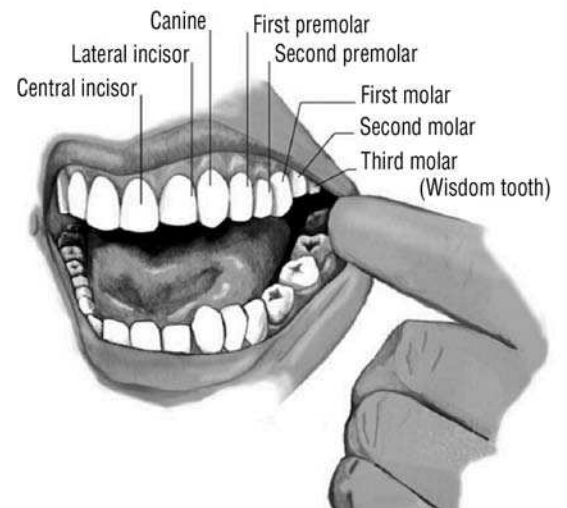
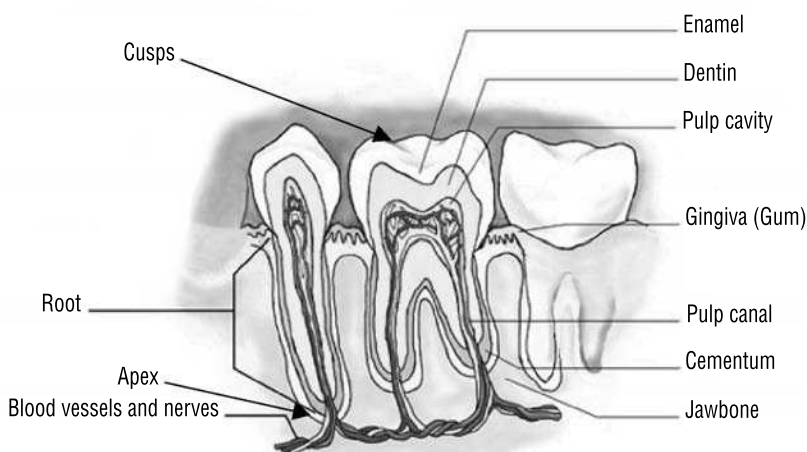
wisdom teeth: also known as third molars

These teeth were developed thousands of years ago when human diets required extra chewing. Wisdom teeth are often removed because they crowd other teeth and are no longer needed for chewing.

Dental Information Page

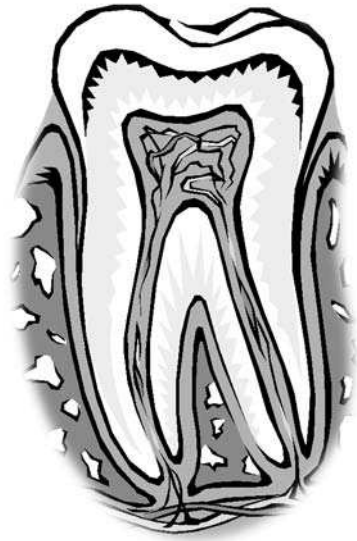
Fun Facts about Teeth

- Humans and most other mammals have two sets of teeth—deciduous, or baby teeth, and permanent teeth.
- Mammals are heterodonts—their teeth are different shapes and sizes and are used for different purposes.
- Fish and reptiles are generally homodonts—their teeth are all the same shape and size.
- Enamel, the outer layer of human teeth, is the hardest substance in the human body.
- Humans have 20 deciduous teeth and 32 permanent teeth.
- Humans have four types of teeth: the incisors cut, the canines tear, and the bicuspids and molars grind food.
- George Washington’s dentures were not made of wood. His dentures consisted of some of his own teeth, cattle teeth, hippopotamus bone, and elephant ivory.
- In 700 B.C. the Etruscans made false teeth out of ivory and bone.
- Human canine teeth are the smallest canines of any mammal.
- Teeth are so resistant to deterioration that, of the human organs, they are the most frequent type of fossilized remains to be found by paleontologists and anthropologists.
- Teeth provide the structure to the muscles in the face and help form the smile.
- The teeth, the lips, and the tongue work together to control the mouth so it can form words.
- Baby teeth erupt once the enamel around them has completely formed.



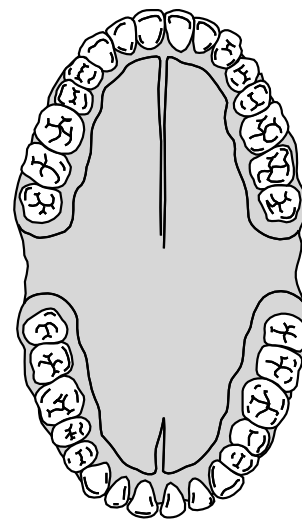
Show What You Know

Label the diagram of the tooth with the words from the vocabulary list below. Write the word in the blank space provided, and draw an arrow to the correct area on the tooth. Arrange the list so that vocabulary words identifying the upper areas of the tooth are on top of the list and those identifying the lower area of the tooth are toward the bottom of the list.



cementum	cusps	root	enamel
crown	pulp cavity	dentin	apex

Label the diagram of the mouth with the words from the vocabulary list below. Write each word in the blank space provided, and draw an arrow to the correct area in the mouth.



central incisors	canines	first molar	third molar
lateral incisors	bicuspid	second molar	

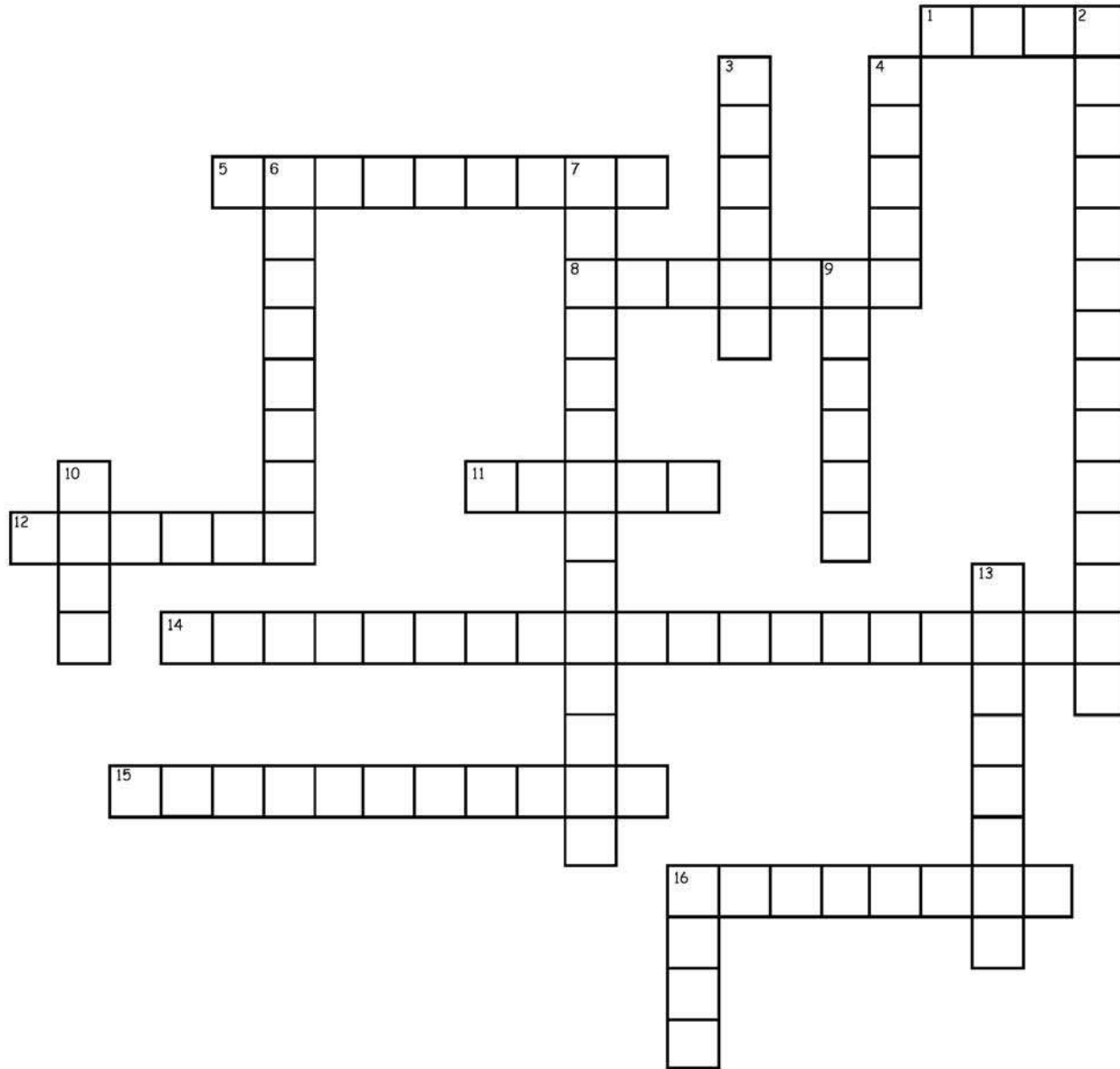
Name _____ Date _____

Dental Word Scramble



1. NRISSOCI _____
2. ASNICEI _____
3. PAEX _____
4. OORT _____
5. DTLRPENAIOTALNMGIE _____
6. LOEASUVL _____
7. MAENEL _____
8. MOWDIS EETH _____
9. DEDUOCISU EHTET _____
10. TDNEIN _____
11. MAPNNEERT ETHTE _____
12. LPUP _____
13. SCPUS _____
14. CISBIDSPU _____
15. LASRMO _____
16. OCNWR _____
17. UTEMMCNE _____

Dental Crossword Puzzle



Across

1. This area consists of blood vessels that bring oxygen and nutrients to the tooth
5. Located behind the canines
8. The name of these teeth comes from their similarity to dogs' fangs
11. Portion of the tooth that is visible above the gum line
12. These teeth are used for the most forceful chewing
14. Attaches the cementum of a tooth to the alveolus
15. Also known as third molars
16. A socket in the jawbone through which the root of a tooth is anchored

Down

2. The 32 teeth that replace baby teeth
3. The layer beneath a tooth's enamel
4. Ridges on top of the crown that are used for grinding and chewing
6. These teeth have a straight, sharp edge and are used to cut food
7. Also known as baby teeth, or milk teeth
9. Forms the outer layer of the tooth and protects it from bacteria and temperature change
10. The portion of the tooth below the gum line
13. Outer layer of the tooth below the gum
16. Bottom point of a tooth's root

Answer Key

Dental Word Scramble

- | | |
|-------------------------|---------------------|
| 1. incisor | 10. dentin |
| 2. canines | 11. permanent teeth |
| 3. apex | 12. pulp |
| 4. root | 13. cusps |
| 5. periodontal ligament | 14. bicuspid |
| 6. alveolus | 15. molars |
| 7. enamel | 16. crown |
| 8. wisdom teeth | 17. cementum |
| 9. deciduous teeth | |

Dental Crossword Puzzle

