

2

Vaginal Bleeding in the First Trimester of Pregnancy

Bastiaan Jager

INTRODUCTION

A health-care provider in the field of gynecology will certainly encounter numerous patients with vaginal bleeding who are unaware of their early pregnancy. All female patients of reproductive age presenting with vaginal bleeding should therefore be assessed for possible pregnancy.

Fortunately, the variety of causes of vaginal bleeding in early pregnancy is limited. However, differentiating between ectopic pregnancy and miscarriage, both common causes of bleeding in early pregnancy, can sometimes be challenging. Diagnostic problems can especially arise in low-resource settings. This chapter specifically helps you prioritize your diagnosis and treatment. It also helps you identify the various causes of vaginal bleeding in the first trimester of pregnancy.

Guidelines for proper history taking and physical examination will be given. After that, signs and symptoms and treatment options will be presented per cause. Finally, we will present a flow chart which should guide you through the most important issues to be considered when encountering a pregnant patient with vaginal bleeding in early pregnancy. The key points that are occasionally presented at the end of a section indicate the minimal standard of knowledge you should have after reading the specific section.

Differential diagnosis of bleeding in early pregnancy

It is not very difficult in itself to diagnose vaginal bleeding in a pregnant patient; the key point is to recognize life-threatening situations which need urgent treatment. Life-threatening conditions are:

ectopic pregnancy, a miscarriage with severe vaginal bleeding and infected abortion with signs of septic shock. Your first step should be to rule out these conditions. The flow chart at the end of the chapter should help you with this. If the patient does not suffer from these serious conditions, one should explore other causes of first-trimester vaginal bleeding.

The differential diagnosis of first-trimester vaginal bleeding is best sub-divided according to anatomical location; therefore your main focus should be to locate the anatomical origin of the bleeding (Table 1).

Table 1 Differential diagnosis of first-trimester vaginal bleeding

Originating from uterus, tubes, amniotic sac with its contents or placenta:

- Ectopic pregnancy (see Chapter 12)
- Miscarriage (see Chapter 13)
- Miscarriage with infection (see Chapter 13)
- Molar pregnancy (see Chapter 27)
- Subchorionic hemorrhage
- Idiopathic bleeding in a viable pregnancy

Originating from cervix or vagina:

- Infection (*Chlamydia*, etc.) (see Chapter 17)
- Trauma (e.g. after intercourse, medical treatment)
- Malignancies, especially cervix cancer (see Chapter 26)
- Cervical abnormalities (e.g. excessive friability or polyps) (see Chapter 9)

Originating from anus, bladder or vulva:

- Hemorrhoids
 - Lacerations of skin due to trauma, malignancy (rare) or infection
 - UTI, schistosomiasis
-

Signs and symptoms of vaginal bleeding in the first trimester

If a woman of reproductive age presents herself at your clinic with vaginal bleeding or any other gynecological problem, always consider the possibility that she might be pregnant. It could be that she is not aware of that herself. If she is aware of her pregnancy, she might have forgotten the date of her last menstrual period. Only after assessing for a possible pregnancy can you start exploring the patient's complaint: vaginal bleeding.

Pregnancy is more likely if the woman has un-specific signs such as: nausea, fatigue, darkened color of nipples and of old scars, swollen and tender breasts and weight gain. If pregnancy is likely, you may confirm this by taking a urine pregnancy test (UPT) or, even better, an ultrasound if available at your facility. Only perform a UPT if you are in doubt of possible pregnancy. This could save costs and more importantly, UPTs might not be readily available in some clinics.

After confirmation of her pregnancy, try to assess the duration (or gestational age) of the pregnancy. This can be obtained by verifying the first day of her last menstrual period. This is called the LMP. With the LMP and Naegele's rule one can estimate the expected date of delivery (EDD) and deduce the gestational age of the pregnancy (Box 1). If the woman does not know the exact LMP, try to make a reasonable estimate of the gestational age in weeks. Naegele's rule assumes an average cycle length of 28 days, which is not true for everyone. There are also pregnancy wheels which help in calculating the EDD and gestational age. Nowadays there are several online calculators as well, e.g. <http://www.medcalc.com>.

After assessing the gestational age of the patient's pregnancy, you should explore her complaint. Suggested questions for assessment of the vaginal bleeding are:

- *Assess the severity* When did the bleeding start? Is there fresh blood (red) or old (darker, brown) blood? Is bleeding daily present? Did it start acutely or gradually? Was it already present before pregnancy? Also try to estimate the amount of blood lost. (Rule of thumb is that when bleeding is less than a woman perceives as a normal menstruation, it probably needs no urgent treatment. Be aware though, as an ectopic pregnancy can present with little loss of blood.)

Box 1 Naegele's rule

An estimated EDD from the first day of the woman's LMP can be found by adding 1 year, subtracting 3 months and adding 7 days to that date. The result is approximately 280 days (40 weeks) from the LMP.

Example:

LMP = 8 May 2009

+1 year = 8 May 2010

−3 months = 8 February 2010

+7 days = 15 February 2010

Note: the calculation method does not always result in 280 days because not all calendar months are the same length and it does not account for leap years. If you want to be correct, you have to use a calendar. Exact 280 days past LMP is found by checking the day of the week of the LMP and adjusting the calculated date to land on the same day of the week.

Using the example above, 8 May 2009 is a Tuesday. The calculated date (15 February) is a Friday; adjusting to the closest Tuesday produces 12 February, which is exactly 280 days past 8 May^{1,2}.

All these questions can give insight in the severity of the case. A woman who suffered from bleeding which started before pregnancy might have cervical or vaginal lacerations due to multiple reasons. A woman with acute bleeding, who has to change her underwear frequently and suffers from accompanying (cramping) abdominal pain, might have a threatening miscarriage or an ectopic pregnancy. Do not forget to check for other accompanying symptoms like nausea and fainting (a sign of hypotension due to 'invisible' intra-abdominal bleeding).

- *Provoked bleeding* Is the bleeding spontaneous or after intercourse or defecation? This could indicate a cervical origin of the problem, e.g. infections like chlamydia and malignancies or even hemorrhoids.

Do ask for other accompanying symptoms:

- Abdominal cramping pain: acute, continuous, localized or general.
- Nausea and fainting might indicate shock due to heavy (intra-abdominal) bleeding in ectopic pregnancy.
- Did she lose any tissue vaginally? This might point towards an incomplete abortion.

- Fever can be a result of recent aseptic procedures or of miscarriage which has been infected. It could also be a symptom of an infection which in itself is correlated with miscarriage, e.g. malaria.
- Dysuria? Sometimes a urinary tract infection (UTI) presents itself with fresh blood in the toilet or stains in her underwear. Painless macro-hematuria is a sign for urinary schistosomiasis.
- Vaginal discharge? This could point towards sexually transmitted infection (STI) such as gonorrhoea. Chlamydia classically presents with painless bleeding or bleeding after intercourse.
- Was there trauma or involuntary sexual intercourse? This could present with lacerations and STI.
- Concurrent infections like malaria can induce a miscarriage and schistosomiasis can cause cervical bleeding, ectopic pregnancy and miscarriage.

Physical examination

You should be aware that the patient might be concerned about losing her pregnancy and therefore she could be emotional. Pay special attention to this when taking her history or performing physical examination.

Assess her recent medical history:

- *Prior medical interventions* Has she been seeking medical attention before and what has been done? She might have had an earlier treatment which has not been aseptic or has been incomplete.
- *Risk of criminal abortion* Did the woman try to conceive? Sometimes women do not dare to admit that they underwent a non-professional (and most of the times septic) abortion. It also gives you a good clue towards the emotional situation of the patient.

Assess her past medical history:

- *Obstetric history* Is this her first pregnancy? There could be a history of miscarriage or bleeding in the first trimester.
- Did she use any drugs? Some drugs are known to increase the risk of miscarriage, e.g. diuretics, anti-epileptic drugs, non-steroidal anti-inflammatory drugs (NSAIDs), misoprostol, retinoids, cytostatic drugs. You might want to check your pharmaceutical reference guides for possible association between drugs and miscarriage. Toxins such as lead, mercury, formaldehyde, ethylene oxide, benzene and large doses of radiation also increase the risk of miscarriage².
- Did she have any operations in the past? An ectopic pregnancy due to pelvic inflammatory disease (PID) can reoccur.
- Did she receive treatment for STIs? PID is a risk factor for ectopic pregnancy.
- Are there known diseases such as diabetes, clotting disorders or HIV? All are risk factors for miscarriage. HIV infection is also a risk factor for developing cervical carcinoma and these patients may have had other STIs.

- Every (gynecological) physical examination should include an assessment of the: blood pressure, temperature and pulse rate.
- After that, examine her abdomen:
 - Scars from previous laparotomies present? An ectopic pregnancy can reoccur.
 - Fundal height to assess the gestational age.
 - Pain located on the uterus? More likely in septic abortion or miscarriage or STI.
 - Pain located laterally or even generalized peritoneal pain? Rule out ectopic pregnancy. Then consider STI, pelvic abscesses or non-gynecological causes of peritonitis (see Chapter 17 on STI).
 - Palpable masses? Ectopic pregnancy, pelvic abscesses, tubo-ovarian masses or non-gynecological tumors (see Chapter 12 on ectopic pregnancy and Chapter 17 on STI).
- Perform a speculum examination (see Chapter 1 on how to do that) to assess whether the blood originates from the cervix, vagina or the uterine cavity. Sometimes the cervix is very friable in pregnancy. Even when gently touched with a speculum, it starts to bleed.
- Perform a digital vaginal examination (see Chapter 1). Be sure to perform the vaginal examination carefully in cases where you suspect an ectopic pregnancy. It can rupture if you manipulate it too much.
 - Assess the ostium of the cervix. If this is open in pregnancy, it is very likely that the woman has either an incomplete miscarriage or an inevitable miscarriage. It should be noted that cervical evaluation is not reliable in distinguishing between complete and incomplete miscarriage³. Sometimes products of

conception are still present in the ostium of the cervix and can be removed during digital vaginal examination. If the ostium is closed, this could indicate a threatening miscarriage, missed abortion or ectopic pregnancy.

- Assess for cervical tenderness. This could indicate an infection or ectopic pregnancy.
- Assess for foreign bodies.
- Assess for cervical masses, malignancies or (rarely) schistosomiasis or tuberculosis (TB). If no blood is found on digital and visual vaginal examination, perform an inspection of the entire genital area. It might be that blood is originating from the urethra, labia, anus or skin. Sometimes patients have difficulties assessing the origin of the blood loss themselves, especially in rural areas where no proper sanitary facilities are present.

Patients without proper diagnosis and on-going complaints after treatment should be referred to a facility where ultrasonic or laboratory investigation is available. If your facility has an ultrasound machine, every patient with first-trimester bleeding should receive an ultrasound investigation to establish a viable intrauterine pregnancy. Rule of thumb for referral is: if a patient (who has not been labelled as having a serious, possibly life-threatening, condition which calls for imminent referral) presents herself three times at a health facility with the same complaint, she should be referred.

Laboratory investigations

It should be noted that most of the causes of vaginal bleeding in the first trimester can be identified after thorough history taking and physical examination. Additional laboratory investigations hardly contribute to the diagnosis.

Possible laboratory investigations

Blood:

- Hemoglobin and cross-matching in case of severe bleeding or suspected ectopic pregnancy. It helps you to estimate the amount of blood lost and helps to anticipate a possible blood transfusion.
- Erythrocyte sedimentation rate (ESR) or leukocytes supposing an infection might be present. (Fever measured by rectal thermometer is more accurate/reliable.) Remember that ESR and

leukocyte count are both slightly elevated in pregnancy.

Urine:

- UPT: urine pregnancy test to confirm pregnancy if in doubt.
- Urine screen for leukocytes, blood. This could indicate UTI. Make sure you explain to the patient how to produce a midstream urine sample (see Chapter 1) to decrease contamination with vaginal blood.

Direct light microscopy:

- Blood slide if signs of malaria.
- Gram stain of urine if you suspect a UTI which is not responding to standard treatment. *Schistosoma* in the urine may indicate (concomitant) genital tract schistosomiasis but can be false negative (see Chapter 9).
- Wet mount or Gram stain of vaginal discharge if suspicious of STIs that are not responding to trial of treatment (see Chapter 17).

Other investigations

Ultrasound

Chapter 1 on gynecological examination presents detailed information on how to perform an ultrasound.

In trained hands, vaginal or abdominal ultrasonography can be crucial in identifying the location of the pregnancy. However, the diagnosis depends on the quality of the ultrasound equipment, the experience of the sonographer, the specific signs and symptoms of the patient and presence of physical factors such as fibroids. The first two factors are often absent in resource-poor settings. So, beware, a pregnant patient with peritoneal pain and signs of hypovolemic shock should have an urgent explorative laparotomy and ultrasound might only delay treatment.

If no intrauterine pregnancy is visible on ultrasound, check for adnexal masses or clear ectopic gestational sacs to confirm the diagnosis. An empty uterus on ultrasound in a patient with a positive UPT should raise the suspicion of ectopic pregnancy at all times. In case of a ruptured ectopic pregnancy, free fluid (blood) will be seen in Douglas' pouch in ultrasound (see Chapter 12 on ectopic pregnancy for more information on diagnostic tools).

Culdocentesis

You can perform a culdocentesis to assess the presence of blood or pus in the pouch of Douglas [see Chapter 12 (culdocentesis) and 18 (culdotomy)]. If you are seriously considering ectopic pregnancy and an ultrasound is not feasible in your setting and culdocentesis does not produce clear results or has failed, you might want to consider a diagnostic (mini) laparotomy as the negative predictive value of culdocentesis is poor⁴.

Diagnostic problems could evolve if a pregnant woman (confirmed by a positive UPT) shows no intrauterine pregnancy on vaginal ultrasonography, has no fluid in Douglas' pouch and has no signs of ectopic masses or gestational sacs. In this case she could have the following conditions:

- she could have had a complete miscarriage,
- she could have a pregnancy too early to be seen on ultrasound,
- she could have a spontaneously resolving intrauterine or tubal pregnancy,
- or she could still have an ectopic pregnancy.

In this case it may be appropriate to admit the patient and reassess her regularly in order not to miss the ectopic pregnancy about to rupture. Do monitor the patient's vital signs on a daily basis. Only, if the UPT has become negative (this can take some time, depending on the gestational age) is it safe to discharge her.

Key points

- Always rule out ectopic pregnancy when encountering a patient with vaginal bleeding early in pregnancy.
- Ectopic pregnancy can be easily mistaken for threatened miscarriage.
- If available, an ultrasound is very useful to differentiate between viable pregnancy, miscarriage and ectopic pregnancy.
- Use culdocentesis to assess for intra-abdominal bleeding.
- Always take proper patient history and perform sufficient physical examination.
- Gynecological physical examination always includes vital signs, assessment of the abdomen, speculum examination and a digital vaginal examination.

Box 2 Danger signs indicating a possible ectopic pregnancy

- Vaginal bleeding and continuous abdominal pain with a closed cervix on digital vaginal examination might be labelled as threatened miscarriage, but could in fact be an ectopic pregnancy. Pain in miscarriage is usually cramping. Pain in ectopic pregnancy is usually continuous and/or accompanied with localized peritonism. If in doubt perform a culdocentesis. If an ultrasound machine is present, assess for the presence of intrauterine pregnancy products and or blood in the pouch of Douglas. If still in doubt perform an explorative (mini) laparotomy.
- Little tissue is obtained on performing a manual vacuum aspiration (MVA). In this case you might have mistaken an ectopic pregnancy for an incomplete abortion or you might have left the gestational sac and its contents behind. One should always obtain tissue when performing an MVA.
- Tachycardia and low blood pressure accompanied by scarce vaginal bleeding. This means that the patient has signs of hypovolemic shock which cannot be explained by the amount of blood lost vaginally alone. The first sign of hypovolemic shock is tachycardia (heartbeat >100bpm). Only after 2 liters of blood, or more, have been lost, a pregnant woman shows signs of drops in blood pressure. Urgent laparotomy is then necessary.
- A woman treated for threatened 'incomplete abortion' who does not respond to misoprostol treatment might have an ectopic pregnancy instead.

MISCARRIAGES

Miscarriage (also known as abortion) is the main reason for vaginal bleeding early in pregnancy. You will find more detailed information about this condition in Chapter 13.

Ten to twenty per cent of clinically recognized pregnancies result in spontaneous miscarriage⁵. The occurrence of ectopic pregnancies is not as high as miscarriage, but is definitely more prevalent in areas where PID is highly endemic. Miscarriage can be a life-threatening condition when it results in massive bleeding (even more in areas where anemia

is prevalent) or septicemia as the result of unsafe, induced abortion. Abortions are unsafe when performed by persons without the proper skills and materials or outside a medically safe environment.

Definitions

By definition, miscarriage refers to the loss of a pregnancy before the fetus has reached a viable gestational age. Unfortunately, the cut-off point for a viable gestational age varies internationally and in time. As a result of progressive medical knowledge neonates can nowadays survive pre-term birth from 23–24 weeks of gestational age onwards. This of course heavily depends on the setting in which neonatal care can be provided and most likely does not apply to your local setting. In short, the gestational cut-off point for a loss of pregnancy to be labelled as miscarriage varies between 16 and 24 weeks^{6,7}. Fortunately, this lack of conformity in definition does not influence the general approach to diagnosis and treatment. In general, one can state that the earlier a miscarriage occurs in pregnancy, the less risk of complications.

In this chapter we will make use of definitions made by the Royal College of Obstetricians and

Gynaecologists (RCOG); a miscarriage refers to the loss of pregnancy below 24 weeks of gestational age. Moreover, the RCOG recommends the medical term for pregnancy loss to be *miscarriage* instead of *abortion*, as abortion also refers to the elective termination of pregnancy which is illegal in most low-resourced countries. The term *miscarriage* acknowledges the emotional aspects of losing a pregnancy and prevents stigmatization of the pregnant woman and her medical caretaker^{8,9}.

The most important subdefinitions for miscarriage and abortion are presented in Table 2.

As mentioned above, miscarriage can be an emotional event for the woman and you should consider this while doing your consultation. In some cultures, stigmatization of the mother and/or partner does occur, but pregnant women and their partners are in fact not to be blamed.

Etiology

The cause of spontaneous miscarriage is in most cases related to the embryo itself. Random morphological abnormalities or absence of the embryo itself are present in approximately 70% of cases of miscarriage before 10 weeks of gestation.

Table 2 Miscarriage: definitions of subcategories

Spontaneous miscarriage	Pregnancy loss within the first 24 weeks of gestation without deliberate interference
Incomplete miscarriage	Pregnancy loss within the first 24 weeks of gestation in which not all products of conception have been expelled at presentation
Recurrent or habitual miscarriage	Three or more consecutive spontaneous abortions/miscarriages
Threatened miscarriage	Uterine bleeding within the first 24 weeks of gestation without any cervical dilation. It is characterized by vaginal bleeding, lower back discomfort or midline pelvic cramping and a risk factor for miscarriage. This condition can be difficult to distinguish from ectopic pregnancy when no ultrasound is present
Missed miscarriage	Retention in the uterus of a dead embryo or fetus which has died within the first 16 weeks of gestation
Induced abortion	The intentional removal of a fetus from the uterus by any of a number of techniques
Criminal abortion	Illegal termination of pregnancy
Legal abortion	Termination of pregnancy under conditions allowed under local or national laws
Therapeutic abortion or induced abortion for medical reasons	Abortion induced to save the life or health of a pregnant woman
Miscarriage with infection or infected abortion	Any type of miscarriage, induced or spontaneous, that is associated with infection of the uterus and its appendages. It is characterized by fever, uterine tenderness, and foul discharge

Morphological abnormalities are most likely the result of random chromosomal abnormalities (50–60%). Most commonly identified: Down's syndrome, also called trisomy 21, polyploidy (more than one pair of chromosomes in the nucleus), Turner's syndrome or monosomy X⁹. The frequency of spontaneous miscarriage increases with maternal age. At the age of 35 years the incidence of spontaneous miscarriage reaches 20% and at the age of 40 it reaches 40–50%¹⁰. Besides age, several maternal conditions can also lead to spontaneous miscarriage:

- Diabetes, thyroid disease and infections, malaria, syphilis, gonorrhoea, cytomegalovirus (CMV), toxoplasmosis, listeria, HIV, parvo-B19, chlamydia, etc.
- Maternal antibodies which predispose to thrombosis such as anticardiolipin and lupus coagulant.
- Genetic thrombophilias (clotting disorders) such as factor V Leiden.
- Acquired or congenital anatomical variations of the uterus: septa, abnormalities of the uterine cavity, myoma, adhesions of the uterine cavity, e.g. Asherman's syndrome after infection.
- Environmental exposure: smoking, alcohol and toxins (lead, heavy metals, organic solvents).
- Medication, e.g. diuretics, anti-epileptic drugs, NSAIDs, misoprostol, retinoids, cytostatic drugs².

Epidemiology

Spontaneous miscarriage is something which actually occurs quite often. Estimates are that one in every eight pregnancies results in a spontaneous miscarriage. Two out of ten women suffer from vaginal bleeding in the first trimester of pregnancy. In 50% of these cases the pregnancy is viable despite the fact that bleeding continues. The other 50% will miscarry sooner or later^{11,12}. It is believed that many (more than 75%) pregnancies are lost before the woman recognizes she is actually pregnant. The clinical signs of the miscarriage are in those cases mistaken for delayed menstruation. As the causes for miscarriage are so various, it is difficult to say who will carry on and who not.

Signs and symptoms

As mentioned the signs and symptoms depend on the specific sort of miscarriage (see Table 2).

Spontaneous miscarriage

Signs are cramping, lower abdominal pain accompanied by clear, red vaginal bleeding. Sometimes tissue and blood clots can be seen as well. Tissue is usually a dark purple color. To differentiate between blood clots and (abortion) tissue you can put the clots/tissue in a glass container with normal tap water and shake: blood clots will resolve, tissue will stay intact. Up to 12 weeks the whole amniotic sac can be evacuated. Physical examination might show uterine enlargement. Digital vaginal examination reveals an open ostium of the cervix, with blood on the finger. In general, the bleeding diminishes dramatically after complete evacuation of the products of pregnancy. An ultrasound is generally not necessary, but if performed, it will show a uterus with double lining endometrium if the miscarriage is complete. Some clots might be present in the fundus (top) of the uterus.

Treatment If the amount of blood lost is less than generally perceived during normal menstruation or is dramatically diminishing, there is no need for specific treatment.

Incomplete miscarriage

This means that a miscarriage has occurred but some products of conception are still present in the uterine cavity. The complaints are similar to those of spontaneous abortion, but in this case the vaginal bleeding has not stopped. Bleeding is usually more than perceived during her normal menstrual period. On digital vaginal examination the ostium of the cervix is still open. On ultrasound one might see clots, parts of the amniotic sac or tissue in the uterine cavity (Figure 1)¹³. Tissue appears as clear white translucencies on the ultrasound, blood clots are less dense in nature, fluid or blood is dark.

Treatment This patient may need treatment with MVA or alternatively she can be treated with misoprostol (see Chapter 13). If, during ultrasound examination, no embryo or fetus is seen and the tissue remaining in the uterine cavity has a diameter of less than 30 mm, expectant management can be considered. But only if the patient is willing and able to come back when bleeding increases or when signs of infection develop. Another precondition for expectant management is that she should have a reasonable Hb.

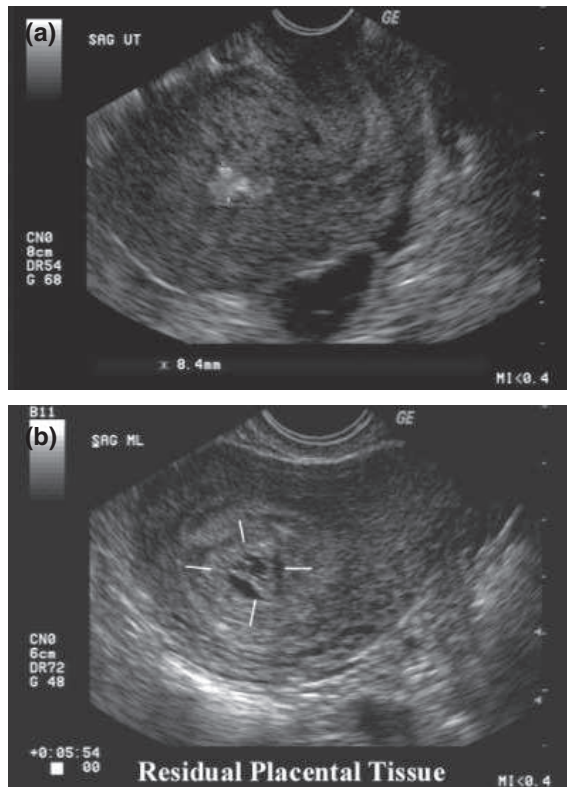


Figure 1 Incomplete miscarriage with placental tissue present in (a) and a diminished amniotic sac in (b).¹³
Source: <http://www.fetalultrasound.com/online/text/4-006.HTM>

Threatened miscarriage

If the pregnancy is viable, the amount of blood lost can be significant. If the Hb level is adequate you may admit the patient and re-assess regularly for increased bleeding. Fifty per cent of these pregnancies continue to be viable. If bleeding is only minimal and the patient has easy access to treatment she may go home and return if bleeding increases.

Missed miscarriage

There are no complaints, but on ultrasound there is an embryo without a heartbeat. Spontaneous miscarriage may follow in days or weeks.

Treatment There are three options and according to your setting you can choose between them: (1) expected management (wait for the pregnancy to terminate itself); (2) start misoprostol and admit patient to ward; (3) perform an MVA.

INFECTED ABORTION

An infected abortion (also called miscarriage with infection) can either be due to prior incomplete spontaneous miscarriage which has not evacuated completely, or due to an aseptic procedure, either criminal or medical. If an MVA is performed under aseptic conditions the uterus or remaining placental tissue could become infected. In countries where there are restrictive laws towards abortion, women might attend traditional healers or try to induce miscarriage themselves when pregnancy is unwanted. Sticks, roots or other septic instruments could be used for the induction of an abortion.

Infected abortion is still a leading cause of death in developing countries. Approximately 100,000 women die annually of infection related to childbirth and unsafe abortion. They account for 15% and 13% of total maternal deaths, respectively. Ninety-nine per cent of maternal deaths occur in developing countries and most of that in sub-Saharan Africa and South-East Asia. On top of this, 20 times more women suffer injury or disease because of infections related to childbirth^{14,15}. As a medical professional one should definitely not miss this diagnosis.

Signs and symptoms

The signs are of a miscarriage accompanied by fever and foul smelling discharge. The patient may develop septic shock. Septic shock has a mortality rate of approximately 25–50%, even with proper treatment in high-care facilities¹⁶. Signs of disseminated sepsis are: high fever and prostration, tachycardia, tachypnea or respiratory distress and low blood pressure¹⁷. In a low-resource setting however, one should already be alerted if a patient presents with fever and tachycardia. If she reports with fever and low blood pressure, septic shock may already be present.

Infecting organisms are usually vaginal or bowel bacteria. Check for signs of abdominal guarding and rebound tenderness to find out if the peritoneal cavity is infected (see Chapter 3 on abdominal pain in the first trimester). This can be due to uterine perforation or infection, tubo-ovarian abscess or bowel perforation.

Treatment

Start imminently on a combination of antibiotics: penicillin, metronidazole and gentamicin (Box 3).

If no signs of septic shock are present, it is probably wiser to perform the MVA after 12–24 h of intravenous antibiotic treatment. In case of septic shock, start with fluid resuscitation and admit to a high-care ward or refer if possible. When performing an MVA look carefully for signs of perforation and for foreign bodies in the vagina or uterus.

Be aware that tetanus could also be the cause of septicemia in settings where there is a low standard rate of vaccination. In case of proper immunization (i.e. five injections in the past 10 years and a booster in pregnancy) one should only give another booster injection of tetanus toxoid 0.5 ml intramuscularly (IM). If the patient has not been immunized before, give anti-tetanus serum 1500 units IM and booster of tetanus toxoid 0.5 ml IM after 4 weeks. Higher doses of anti-tetanus serum are needed in clear cases of tetanus. Check your local guidelines¹⁸.

If possible at your facility, take vaginal swabs for culture and blood cultures for antibiotic sensitivity testing¹⁹. Be careful, an infected uterus is easily perforated on evacuation.

When signs of abdominal guarding and rebound tenderness are present, a perforation of the uterus might already be present and a culdocentesis or laparotomy should be considered.

Box 3 Antibiotics for infected abortion

Benzylpenicillin intravenously (IV) 5 million IU q.d.s. or ampicillin 2g IV q.d.s. (2nd choice amoxicillin 500mg tablets t.d.s.)

plus

Metronidazole 500mg IV t.d.s. or 500mg tablets (orally or rectally)

plus

Gentamicin 5 mg/kg o.d. IM

If fever has resided for 24h one can start 1 week of oral treatment with amoxicillin and metronidazole.

Key points

- Infected abortion is one of the leading causes of maternal death worldwide.
- Professionals should be aware that septic shock is present when patients present with fever accompanied by tachycardia and/or low blood pressure.

- Removal of aseptic products and a combination of antibiotics is mandatory treatment.
- Start fluid resuscitation, antibiotics and adrenalin (optional) if clear signs of septic shock.
- If signs of peritoneal guarding or rebound tenderness are present, consider that she may also have a perforated uterus or even a bowel perforation.
- Take cultures if possible at your facility.

MOLAR PREGNANCY (HYDATIDIFORM MOLE, GESTATIONAL TROPHOBLASTIC DISEASE)

A molar pregnancy is an abnormal form of pregnancy where a non-viable, fertilized egg becomes a pathological pregnancy. The chorionic villi around the fetus degenerate and form clusters of fluid-filled sacs, hence the name molar pregnancy (Figure 2). Detailed information on diagnosis and treatment of a molar pregnancy can be found in Chapter 27.

Clinically, the patient will show signs and symptoms of normal pregnancy. These signs and symptoms could even be more prominent due to abnormally high levels of human chorionic gonadotropin (hCG) (produced by the trophoblast cells): nausea and vomiting leading to hyperemesis gravidarum, enhanced pigmentation of nipples, scars and moles, painful breasts and signs of early pre-eclampsia. Painless vaginal bleeding is the rule. Loss of vesicles is characteristic for molar pregnancy. A dough-like uterus which is usually too large for gestational age can be palpated. hCG levels can

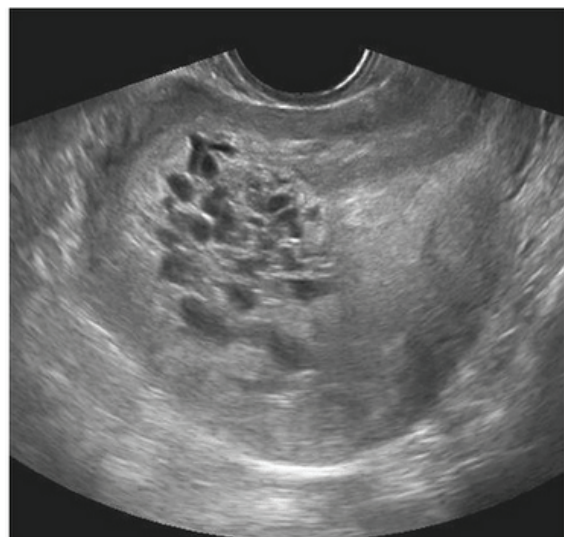


Figure 2 Typical ultrasound picture of a hydatidiform mole

vary and range from excessively high in early pregnancy (>100,000 IU/ml) to normal and slowly rising in case of a partial molar pregnancy.

Conclusive diagnosis can only be made by histopathology, which is scarcely available in low-resource settings. Histopathological diagnosis reveals hydropic swelling of the chorionic villi and hyperplasia of the trophoblastic cells.

Treatment

Evacuation of the uterus as described in Chapter 27. Be aware that massive hemorrhage can occur during MVA. Do have blood compounds available!

Key points

- Hydatidiform mole is difficult to diagnose, but can lead to serious complications.

CERVICAL MALIGNANCIES

In Western settings, screening programs have significantly reduced the prevalence and mortality of cervical carcinoma. In developing countries however, cervical carcinoma is the most common malignancy in women. The malignancy usually presents itself at 30–50 years of age^{20,21}. HIV-infected persons are more susceptible to cervical carcinoma. As a result, it is not unusual to encounter a cervical carcinoma in pregnancy in low-resourced settings. Unfortunately, medical professionals are usually not aware that a cervical malignancy might be a possibility when encountering (recurrent, minimal) vaginal bleeding in pregnancy. The key to a proper diagnosis is speculum examination and digital vaginal examination. Needless to say that vaginal examination is not contraindicated in pregnancy, only when rupture of membranes is confirmed.

Signs and symptoms

The signs are vaginal bleeding due to cervical erosions. Cervical erosions develop as a result of malignancies or infections. Bleeding can occur spontaneously, but classically, due to direct contact of the cervix, i.e. vaginal bleeding after intercourse, inserting tampons or passage of hard stools. Bleeding due to cervical erosions is usually self-limiting and not severe (as in miscarriage or ectopic pregnancy). On digital vaginal examination a solid, painless mass or irregularity is palpated. Bleeding can be triggered due to digital examination. There

is usually no cervical tenderness. Depending on the stage of the malignancy, the whole vaginal wall and rectum can be included in the lesion as well. The lesions can become necrotic and infected. As a result cervical malignancies are very often quite smelly. In Chapter 26 cervical carcinoma is discussed in depth.

INFECTIONS THAT CAUSE (VAGINAL) BLEEDING

The infections that can cause vaginal bleeding are presented below. For a thorough outline of STIs, please see Chapter 17.

Chlamydia

This usually goes unnoticed in female patients. Sometimes it causes painless vaginal bleeding. In fact this is a classical symptom. Every woman presenting with painless vaginal bleeding should be checked for chlamydia if no instant cause has been found. When untreated it has a high prevalence of resulting in PID. This is not very likely to happen during pregnancy however. When inspecting the cervix with a speculum a reddish, infected cervix can be seen, sometimes accompanied by yellow purulent discharge; it bleeds easily on touch.

Treatment

Use your national guidelines for STI treatment. In pregnancy doxycycline is contraindicated, but erythromycin 500 mg q.d.s. for 2 weeks is adequate as well. Do not forget to treat the partner as well.

Gonorrhoea

Fifty per cent of the patients with gonorrhoea are asymptomatic. In symptomatic patients with gonorrhoea, dysuria, vaginal discharge and bleeding may be present. On examination cervicitis with purulent discharge can be seen. For treatment see Chapter 17.

Urogenital schistosomiasis

This is caused by a parasite called *Schistosoma haematobium* or *S. japonicum*. It is endemic in some areas in the tropics. Its main symptom is painless hematuria, which can be mistaken for vaginal bleeding. In addition, schistosomiasis can mimic cervical cancer with bleeding from an ulcerated cervix or it can

mimic cervicitis. Genital schistosomiasis can cause ectopic pregnancy through specific granulomata in the tubal wall as well as miscarriage through an endometritis (see Chapter 9 for diagnostics).

Treatment

Praziquantel 40 mg/kg body weight as a single dose is recommended outside pregnancy. However, as praziquantel is contraindicated in pregnancy, treatment has to be postponed until after delivery.

Urogenital tuberculosis

Due to increasing co-infection with HIV, genital TB is more frequently seen; previously it was quite uncommon. Many TB patients have difficulties getting pregnant at all because of subfertility due to the disease. TB can lead to bleeding due to endometritis and miscarriage or ectopic pregnancy through chronic TB salpingitis. Additionally, genitourinary TB can mimic signs and symptoms of a UTI.

When you suspect a patient of urogenital TB, check for concurrent symptoms such as cough, enlarged lymph nodes, ascites and sterile pyuria or hematuria. Also check for other TB cases in the direct family and perform a chest X-ray. When urogenital TB is present, counsel the patient for HIV testing.

Treatment

Tuberculostatics according to local protocols. Treatment is mostly given by directly observed treatment (DOTS).

Urinary tract infection

A lower urinary tract infection (or cystitis) can cause hematuria and can easily be mistaken for vaginal bleeding. A lower urinary tract infection is a fairly common condition in pregnancy due to increased urinary stasis. In pregnancy it can present itself with mild symptoms, but dysuria, lower abdominal pain, hematuria, frequent micturation and incontinence are all possible symptoms. The infection is usually caused by the bacterium *Escherichia coli* or enterococci (bacteria originating from the gut). *E. coli* is becoming more resistant to penicillin nowadays.

Diagnosis can be confirmed by a dipstick of a midstream urine specimen. In some persistent cases a culture is mandatory before repeating treatment.

An upper urinary tract infection (or pyelonephritis) is a more serious condition which calls for intravenous antibiotics.

Treatment

Nitrofurantoin 50 mg q.d.s. for 3–5 days. Alternative regimes are: amoxicillin/clavulanic acid 625 mg t.d.s. for 5 days or (only in the first trimester) cotrimoxazole 960 mg b.d.

OTHER CONDITIONS CAUSING VAGINAL BLEEDING

This section contains incidental causes of vaginal bleeding in early pregnancy. They usually do not urge for a treatment. Diagnosis can only be made on direct sight or when conditions like miscarriage, ectopic and molar pregnancy, infections and malignancies have been excluded.

Cervical polyps

These do sometimes present in pregnancy. In general they bleed after intercourse, but also spontaneously. Most polyps do not bleed profusely. Diagnosis is made on speculum examination. A typical polyp consists of mucosa similar to the vaginal–cervical mucosa; it is soft and painless. The stem of the polyp is usually avascular.

If services are available at your center, you may send a specimen for histological confirmation. The majority (99%) of cervical polyps are benign.

Treatment

A cervical polyp can easily be removed by clamping it with a sponge-holding forceps: grasp the polyp and gently turn clockwise until it loosens. This procedure is usually painless. There is only minimal bleeding. Alternatively, when the stalk of a polyp is broad you may consider ligating it and cutting it off. It is recommended that this is done several weeks after the delivery.

Friable cervix

In some women the cervix is extremely friable in pregnancy. In pregnancy the endocervical epithelium (that is usually inside the ostium) everts and becomes the exterior portion of the cervix. This ectropion will bleed easily on contact.

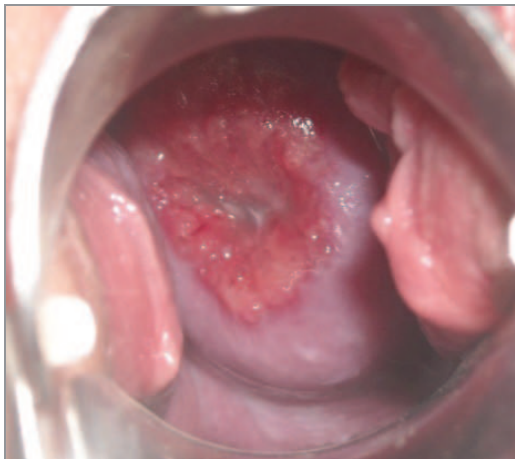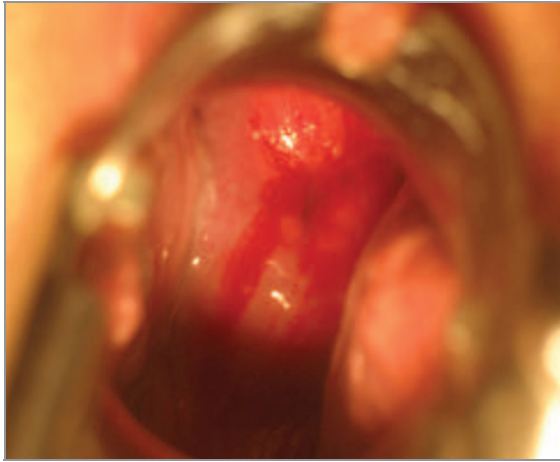


Figure 3 Examples of ectropion

On physical examination with a speculum, there is no clear discharge or generalized reddish cervix to be seen as in an infected cervix. The ectropion is a very specific shallow, vascular, red area (Figure 3).

Treatment

Besides reassurance a friable cervix needs no specific treatment. In some cases if bleeding is persistent, and VIA (see Chapter 26) is negative, one could cryocoagulate the bleeding part of the ectropion. Only do this several weeks after delivery.

Vaginal or perigenital lacerations

These are easily diagnosed if a proper physical examination is performed. They can be a result of trauma or a skin infection like fungal infection or eczema. Be careful, some STIs involve the

perigenital skin as well, such as lymphogranuloma venereum.

Subchorionic or idiopathic bleeding

This can only be diagnosed if other (more serious) causes have been excluded. Idiopathic means that no specific cause can be found. In some cases the blood originates from the subchorionic area. In theory, due to growth of the uterus and its components in pregnancy, small lacerations occur below the chorionic layer and the uterine wall which presents as fresh vaginal bleeding. On direct inspection using a speculum, one can clearly see blood coming straight out of the ostium of the cervix.

Treatment

Subchorionic or idiopathic bleeding needs reassurance, but no specific treatment. Sometimes subchorionic hematomas may lead to bothersome uterine contractions or even miscarriage. In 10% of cases the bleeding re-occurs. The woman should be informed about that.

Hemorrhoids

Hemorrhoids are also easily diagnosed. Sometimes anal bleeding is mistaken for vaginal bleeding. Usually it is sufficient to ask the patient and confirm by physical examination. They usually disappear after pregnancy and conservative treatment is your first option; painkiller (local) and laxatives may be added if hard stools are present as well.

Key points

- The incidental causes of bleeding in the first trimester should only be diagnosed if more serious conditions of miscarriage, ectopic pregnancy, infections and malignancies have been ruled out first.

A flow chart for the diagnosis and management of first-trimester vaginal bleeding is shown in the Appendix.

REFERENCES

1. Cunningham FG, McDonalds PC, Gant NF, et al. *Williams Obstetrics*, 20th edn. Stamford, Connecticut: Appleton & Lange, 1997
2. Duff P, Edwards RK, Davis JD, et al. *Obstetrics & Gynaecology: Just the Facts*. New York: McGraw-Hill, 2004

3. Wieringade-Waard M, Bonsel GJ, Ankum WM, *et al.* Threatened miscarriage in general practice: diagnostic value of history taking and physical examination. *Br J Gen Pract* 2002;52:825–9
4. Royal College of Gynaecology. *The Management of Tubal Pregnancy*. RCOG Green-top guideline 21. http://www.rcog.org.uk/files/rcog-corp/GTG21_230611.pdf
5. Alberman E. Spontaneous abortion: epidemiology. In: Stabile S, Grudzinkas G, Chard T, eds. *Spontaneous Abortion: Diagnosis and Treatment*. London: Springer-Verlag, 1992;9–20
6. Regan L, Rai R. Epidemiology and the medical causes of miscarriage. *Baillieres Clin Obstet Gynaecol* 2000;14:839–54
7. Heineman MJ, Bleker OP, Evers JLH, *et al.* *Obstetrie en Gynaecologie; de voortplanting van de mens*. Maarssen: Elsevier/Bunge, 1999
8. Royal College of Gynaecology. *Management of Early Pregnancy*. RCOG Green-top guideline 25. <http://www.rcog.org.uk/womens-health/clinical-guidance/management-early-pregnancy-loss-green-top-25>
9. Griebel CP, Halvorsen J, Golemon TB, *et al.* Management of spontaneous abortion. *Am Fam Phys* 2005;72:1243–50.
10. Nybo-Andersen AM, Wohlfahrt J, Christens P, *et al.* Maternal age and fetal loss: population based register linkage study. *BMJ* 2000;320:1708–12
11. Everett C. Incidence and outcome of bleeding before the 20th week of pregnancy: prospective study from general practice. *BMJ* 1997;315:32–4
12. Wilcox AJ, Weinberg CR, O'Connor JF *et al.* Incidence of early loss of pregnancy. *N Engl J Med* 1988;319:189–94
13. Suchet IB. Incomplete abortion In: *The Ultrasound of Life*. <http://www.fetalultrasound.com/online/text/4-006.HTM>
14. World Health Organization. Why do so many women still die in pregnancy or childbirth? <http://www.who.int/features/qa/12/en/sindex.html>
15. Grimes DA, Benson J, Singh S, *et al.* Unsafe abortion: the preventable pandemic. *Lancet* 2006;368:1908–19
16. Kumar V, Abbas AK, Fausto N, *et al.* *Robbins Basic Pathology*, 8th edn. Philadelphia: Saunders, 2007;102–3.
17. Stubblefield PG, Averbach SH, Grimes DA. Septic abortion: prevention and management. *Glob. libr. women's med.* (ISSN: 1756–2228), 2008 (updated 2012)
18. Eddleston M, Pierine S. *Oxford Handbook of Tropical Medicine*. Oxford: Oxford University Press (ISBN 0192627724), 2002
19. Department of Reproductive Health and Research. *Managing Complications in Pregnancy and Childbirth: a guide for midwives and doctors*. Department of Reproductive Health and Research, WHO library, 2005. http://whqlibdoc.who.int/hq/2000/WHO_RHR_00.7.pdf
20. Onwudiegwu U, Bako A, Oyewumi A. Cervical cancer – a neglected health tragedy. *J Obstet Gynaecol* 1999;19:61–4
21. Cancer Research UK. Cervical cancer – UK incidence statistics. <http://info.cancerresearchuk.org/cancerstats/types/cervix/incidence>

APPENDIX – Flowchart for management of first-trimester vaginal bleeding

