



**BSM** | *Connection*<sup>™</sup> for Ophthalmology

# BSM *Connection*<sup>™</sup> eLearning Course

## Anatomy and Physiology of the Eye

## Table of Contents

<b>OVERVIEW</b> .....	1
<b>VISION AND THE VISUAL SYSTEM</b> .....	1
<b>THE GLOBE AND ITS TOPOGRAPHY</b> .....	1
<b>ADNEXA</b> .....	3
<b>TEAR FILM</b> .....	6
<b>ANATOMY AND PHYSIOLOGY OF THE EYEBALL</b> .....	7
<b>PUPILLARY PATHWAYS</b> .....	13
<b>INNERVATIONAL PATHWAYS</b> .....	14
<b>EXTRAOCULAR MUSCLES</b> .....	15
<b>VISUAL PATHWAY</b> .....	17
<b>CONCLUSION</b> .....	18
<b>COURSE EXAMINATION</b> .....	19

# Anatomy and Physiology of the Eye

## OVERVIEW

The eye is an extremely complex organ comprising myriad structures that work together to provide the sense of sight. An understanding of the anatomy and physiology of the visual system provides eye care professionals and staff with a valuable tool when meeting their patients' needs and expectations.

This course is designed to provide eye care staff with a detailed, up-close look at the human eye, and help transfer that knowledge to enhance their ability to provide quality care to patients.

## VISION AND THE VISUAL SYSTEM

The task of the visual system is a big one: This system must process an almost infinite amount of available information and extract only the bits that are useful. The brain gives different regions of the visual field different priorities. The visual system seems to be a combination of several visual subsystems: one dedicated to color, another to form, and a third to motion and depth.

The visual system is the part of the central nervous system that enables the human organism to see. By interpreting the information from visible light, it builds a representation of the world surrounding the body. White light is reflected off an object, enters the eye through the cornea, and proceeds down the visual axis (line bisecting the eye) to the center of the retina, the fovea. The receptors in the retina convert this light to electrons that are then transmitted to the visual cortex in the brain, where the image is "seen."

## THE GLOBE AND ITS TOPOGRAPHY

The globe of the eye, or *bulbus oculi*, is a bulb-like structure consisting of a wall enclosing a fluid-filled cavity. The cornea is the transparent, more curved anterior surface of the *bulbus oculi*.

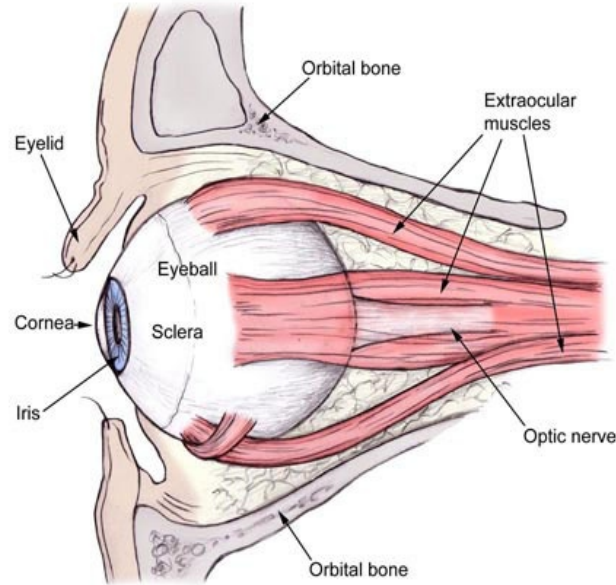
**Embryology:** Eyes develop in the fetus during the second week of pregnancy. The formation of the eye is primarily a product of different cell growth rates, as well as cellular specialization as development takes place. The optic cup predetermines the size and shape of the orbit. Postnatal growth of the orbit coincides with growth of the globe. Eyelids start out fused together and separate between the fifth and the seventh month. Most babies are hyperopic, or farsighted, at birth.

**Dimensions, shape, and position:** The anterior 1/6th-inch of the *surface* of the eyeball, known as the window of the eye, is the clear, dome-shaped cornea. The remaining 5/6-inch is the white, opaque, fibrous sclera. The center of the cornea is known as the anterior pole of the eye and opposite it, at the back of the eye, is the posterior pole. The average axial length of the adult globe is 23.5 millimeters. This equals the diameter from the outermost point of the cornea to the orbital fat behind the retina. The mature cornea measures 12.0 millimeters across the diameter.

The *geometric axis* is an invisible line that bisects the eye exactly, anterior to posterior. The *geometric equator* refers to the greatest circle around the eye, perpendicular to the geometric axis. The equator is 15 millimeters posterior to the corneal limbus, which is the juncture of the sclera, cornea and iris.

**Divisions of the globe:** The **anterior segment** is the front third of the eye and includes all structures in front of the vitreous: the cornea, iris, ciliary body and lens. The two fluid-filled chambers within the anterior segment are: The *anterior chamber*, which is the space between the posterior cornea (endothelium) and the iris, and is filled with aqueous fluid. The *posterior chamber* is the area behind the iris and in front of the vitreous face, and is filled with aqueous fluid. The aqueous in both anterior and posterior chambers provides nutrients to the surrounding structures. The **posterior segment** is the posterior two-thirds of the eye and includes the clear, jelly-like vitreous, the anterior hyaloid membrane of the vitreous, retina, choroid, and optic nerve.

# Anatomy and Physiology of the Eye



*Eye and orbit*

**The bony orbit:** Two bony orbits, often called the “sockets,” are on either side of the nose in the front of the skull. They are pyramidal, with the wide opening on the front of the orbit analogous to the base, while the tip of the pyramid points towards the brain. The orbits create a diverging outward angle of 23 degrees with respect to the midline of the skull.

- The volume of the orbit is approximately 30 cubic centimeters with an entrance dimension of 35 millimeters high and 45 millimeters wide. Behind the orbital margin is the maximum size of 1 centimeter. Orbital depth in the adult orbit is 40-45 millimeters from entrance to exit. The globe takes up about a fifth of the orbit.
- The two lateral walls form a 90-degree angle with each other. Surrounding the orbit anteriorly is the nasal cavity, and posteriorly the ethmoid and sphenoid sinuses. Because of the proximity of the orbit to the sinuses, this is a primary route for the spread of infection and inflammation between the eye and the sinus.
- The functions of the orbit are to provide protection, support, and attachment for the muscles that control eyeball movement.
- The orbital roof is the frontal bone, and the lesser wing of the sphenoid bone is at the back end of the roof. It is here where the lacrimal gland is located in the upper lateral region. Medially, the trochlea is 4 millimeters from the orbital margin, forming the pulley of the superior oblique muscle tendon.
- The medial wall of the orbit consists of four bones: maxillary, lacrimal, ethmoid and the lesser wing of the sphenoid. The paper-thin ethmoid is the thinnest of these bones and makes up the largest portion of the medial wall. This is known as the lamina papyracea, and inferiorly it is continuous with the nasolacrimal canal.
- The zygomatic bone and greater wing of the sphenoid form the lateral wall. This represents the strongest and thickest of the orbital walls.

ORBITAL BONES
Frontal
Ethmoid
Sphenoid
Zygomatic (strongest)
Maxilla
Lacrimal
Palatine (smallest)

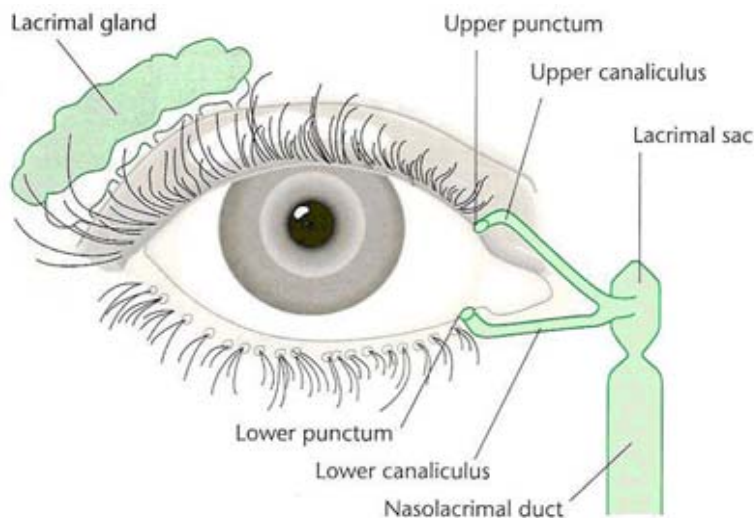
## Anatomy and Physiology of the Eye

- The orbital floor actually comprises bones: maxillary, palatine, and zygomatic. The origin of the inferior oblique muscle is here and represents the only extraocular muscle origin not at the orbital apex. The thin orbital floor is susceptible to blunt trauma, often causing a blowout fracture.
- Openings in the orbit allow blood vessels and nerves to travel to and from the globe and orbit. There are two types of openings:
  1. The optic **foramina** (holes) are openings in the orbit that allow blood vessels and nerves to pass to and from the orbit. Optic foramina are the major holes that lead from the medial cranial fossa to the orbital apex transmitting the optic nerve (cranial nerve II), the ophthalmic artery, and sympathetic nerve fibers of the carotid plexus.
  2. **Fissures** are longer openings in the orbit allowing transmission of nerves and blood vessels.
    - The superior orbital fissure is 22 millimeters long, and located inferior and lateral to the optic foramina. This is subdivided into two parts: the superior portion, transmitting trochlear nerve (cranial nerve IV) and the lacrimal and frontal branch of cranial nerve V; and the inferior portion which the medial rectus origin separates from the superior portion. Passing through this location are the abducens nerve (cranial nerve VI), divisions of the oculomotor nerve (cranial nerve III), and nasociliary branches of cranial nerve V, the superior ophthalmic vein.
    - The inferior orbital fissure is below the superior orbital fissure between the lateral wall and the orbital floor. Transmitted through this fissure are the maxillary and pterygoid portion of cranial nerve V and the inferior ophthalmic vein prior to entering the cavernous sinus.

Six of the 12 cranial nerves directly innervate the eye as well as the surrounding periocular tissues. Cranial nerves, II, III, IV, V, VI, and VIII are transmitted through the orbit to the eye.

### ADNEXA

“Adnexa” stems from a Latin word meaning “appendages”: In this usage, it refers to the appendages of the eye. The accessory visual structures of the eye include both the visual eyebrow and eyelids as well as the lacrimal apparatus. The adnexa also serves to provide anatomic boundaries for the eyelids.

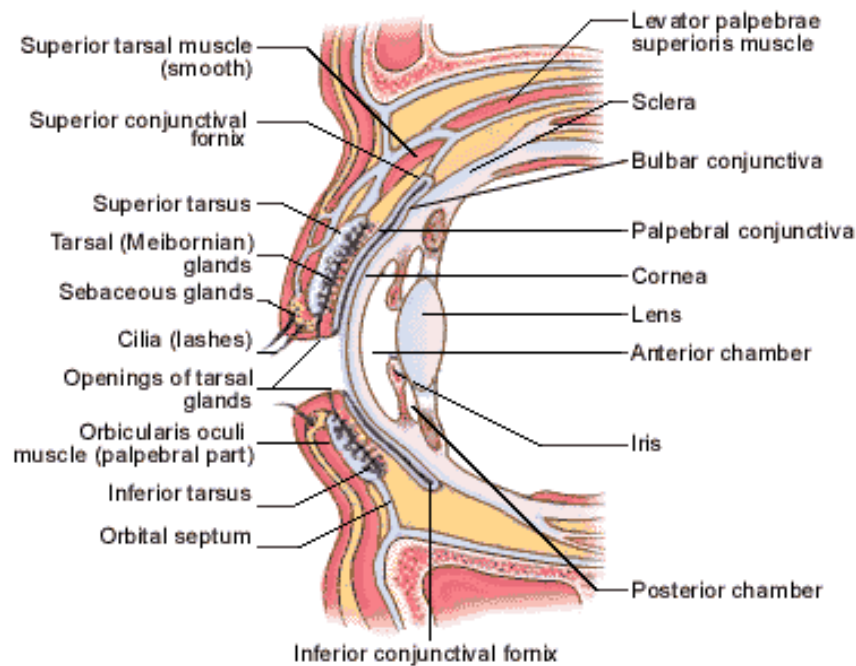


*Lacrimal apparatus*

# Anatomy and Physiology of the Eye

**Eyelids** are the flexible and mobile multilayer structures that cover the eye anteriorly. When the eyelids are closed, they cover the globe. The primary function of the lids is to protect the eye from bright lights and foreign objects. The blinking action also serves to protect the cornea from drying. The tear film is spread over the surface of the eye at the rate of five times per minute. Blinking also aids in the tear flow from the lacrimal glands and the aspiration of tears into the nasolacrimal system. Structures in the eyelid contribute to the production of tear film.

The upper and lower eyelids connect nasally and temporally at the canthi to form an opening 30 millimeters wide and 10-12 millimeters high. Upper lids run from the upper lash line to the eyebrow. The lower lid extends from the lower lash line to the upper cheek. The palpebral fissure is the space between the lids when they are open and should be symmetrical between both eyes. When the eye is in the primary position, the upper lid should lay on the superior corneal limbus while the lower lid rests on, or at a millimeter below, the inferior corneal limbus.



*Anatomy of the eyelid*

# Anatomy and Physiology of the Eye

## LAYERS OF THE EYELID

The **skin** of the eyelid is very mobile, elastic, and thin. The attachment of this skin to the underlying structure is very loose. The skin also contains sebaceous glands, fine hairs, and sweat glands. The margin of the eyelid has some important structures:

1. The *punctum* is a small, 0.3-millimeter opening in the nasal area of each upper and lower eyelid. This connects to the lacrimal sac by the junction formed by the canaliculus, a small tube connected to both the upper and lower puncta.
2. The *gray line* is a pigmented line along the length of the lid margin. Surgeons use this gray line as a line of demarcation. Lashes arise anterior to the gray line.
3. The *meibomian glands* are sebaceous glands that rise behind the gray line. There are 30-40 gland orifices in the upper lid and 20-30 in the lower lid. Meibomian glands are embedded in the tarsus and run vertically along each lid, secreting lipids, or oils, which create the outermost layer of the tear film and help prevent tear evaporation.

**Subcutaneous connective tissue** is loose and has no fat.

The **obicularis muscle**, the main depressor of the lids, provides lid closure and contracts during blinking, which protects the eye from foreign bodies. Blinking also aids in spreading and maintaining the tear film. It is an elliptical muscle that occurs in concentric bands deep in the subcutaneous tissue of the eyelids. The obicularis is attached with medial and lateral canthal tendons. The muscle fibers arc around each lid over the orbital septum. The contraction of these fibers helps in the pumping mechanism of the lacrimal system. The obicularis is responsible for Bell's phenomenon, which is a normal reflex that occurs when lids are closed. The eyes retract underneath the upper lids. The innervation of this muscle is from cranial nerve VII (facial).

The **orbital septum** is a thin sheet of connective tissue acting as a barrier between the orbit and eyelids. It is located behind the obicularis and prevents the orbital fat from moving forward. This action helps prevent the spread of infection, blood, inflammation, and edema.

The smooth **levator muscle** is the main elevator of the upper eyelid. It originates in the orbital apex with the superior rectus and superior oblique. It is 50-55 millimeters long, with fingerlike projections, providing a broad insertion into the anterior surface of the tarsus, creating a lid crease. There are also attachments to the conjunctiva in the upper fornix with the orbital septum. Its innervation is cranial nerve III. The origin of **Mueller's muscle** is at the belly of the levator muscle. Its insertion is into the tarsal border. Innervation of Mueller's muscle is from the sympathetic system, lifting the upper lid 2-3 mm.

The **tarsal plate** is dense connective tissue 1 to 1.5 millimeters thick that gives the upper (11 millimeters high) and lower (5 millimeters high) eyelids shape, rigidity, and structure. Each plate is 25 millimeters wide and curves to conform to the shape of the globe. There are firm attachments superiorly and inferiorly to the orbital septum and to the bony orbit by medial and lateral canthal tendons. The lipid-secreting meibomian glands are embedded into the tarsal plate.

The **conjunctiva** is a transparent, vascular, mucous membrane that lines the inside of the eyelids then reflects back and covers the anterior surface of the globe. The junctions between these areas are known as the superior and inferior fornices. The **palpebral** conjunctiva refers to the firm attachment to the tarsal surface of the lids, whereas the **bulbar** conjunctiva is attached loosely to the globe and inserts in the area of the limbus.

**Eyebrows** are thick skin, with several rows of hair that extend across the superior orbital margin, separating the skin of the upper lid from the forehead. Movements from muscles surrounding the eyebrows contribute to facial expression; the brows themselves protect the eyes from perspiration and other debris.

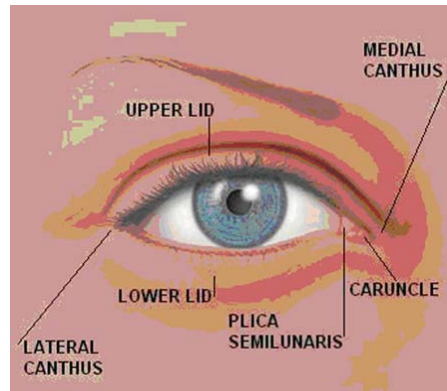
**Eyelashes** consist of rows of hair (cilia) rising from follicles running along the length of both upper (five to six rows) and lower (three to four) eyelids. Lashes act as a protective mechanism: The approach of foreign particles causes a blink reflex in the eyelids, which are sensitive to touch. Sebaceous glands

# Anatomy and Physiology of the Eye

(glands of Zeis) at the base of each lash, and Moll glands (modified sweat glands), contribute to the normal tear layer lubricating the ocular surface.

The **medial canthus** is the nasal corner of the eye, 180 degrees opposite the lateral canthus:

- The **plica** is the crescent-shaped fold nasally.
- The **caruncle** is the fleshy body at the medial canthus, containing sebaceous and sweat glands.



*Frontal view of the eyelid*

## TEAR FILM

Precorneal tear film lies just anterior to the globe, is 6-10 microns thick, and consists of three layers: superficial lipid layer, middle aqueous, and inner mucin. The normal tear volume in the conjunctival sac is 3-7 microliters but can increase up to 25 microliters before overflow occurs at the lid margin. Tear flow originates in both the lacrimal gland and accessory lacrimal glands at a rate of approximately 1 microliter per minute. Tears have a pH of 7.6 and an osmolarity similar to sodium chloride at 0.9 percent. The pH (potential hydrogen) is almost neutral, which is important in the manufacture of eye drops. When the neutrality is too acidic (lower pH) or too alkaline, (higher pH), the comfort and health of the eye are compromised. The functions of the tear film are to:

- Lubricate the cornea to maintain a smooth optical surface for refracting light rays.
- Provide oxygen, nutrients, lysozyme, and other immunoglobulins for nourishment and antibacterial factors.
- Flush away debris from the corneal surface

The three **tear film** layers (lipid, aqueous, and mucin) follow below:

1. The *lipid layer* is the most superficial layer, produced mainly by meibomian glands, with some lipids from the glands of Zeis and Moll. The major functions of the lipids are to:
  - Prevent evaporation of the tears.
  - Provide lubrication so the lids move smoothly over the globe.
  - Contribute to the optical properties.
  - Maintain a lipid strip at the lid margin preventing tear overflow by increasing surface tension.



## Anatomy and Physiology of the Eye

2. The middle *aqueous layer* comes from the main lacrimal gland and the glands of Krause and Wolfring. It consists of water, proteins and electrolytes. The major functions of the aqueous layer are to:
  - Supply oxygen to the avascular cornea while maintaining the osmotic gradient to remove fluid from the cornea.
  - Provide an antibacterial environment to the eye through proteins, immunoglobins, and lysozyme within the aqueous layer.
  - Maintain a smooth surface by filling in the irregularities of the anterior surface.
  - Wash away surface debris towards the puncta.
3. The *mucin layer* is the most posterior layer of the tear film and is closest to the corneal surface. The goblet cells of the conjunctiva secrete mucin, which turns the cornea from a *hydrophobic* (water-repellent) surface into a *hydrophilic* (water-loving) surface by coating the irregular corneal epithelium to distribute the tear film evenly. The major functions of the mucin layer are to:
  - Interact with the lipid layer to stabilize the tear film.
  - Help collect loose cells, foreign particles, and bacteria in the network on the bulbar conjunctiva.

Tear dysfunction occurs when there is an imbalance of the tear film components. There can be too much aqueous or lipid, or not enough mucin. Excess tearing or dry eyes are symptomatic of this imbalance.

### ANATOMY AND PHYSIOLOGY OF THE EYEBALL

The eye consists of three layers: the fibrous, vascular, and nerve layers, and additionally, the ocular media. Following is a description of these layers and their functions.

**Fibrous Layer:** The fibrous layer is the outer layer of the eye, consisting of two parts, the cornea and the sclera.

The **cornea** is an avascular, transparent organ, the clear, dome-like structure in front of the visible iris. It is a convex structure with a horizontal diameter of 12 millimeters and a vertical measurement of 10-11 millimeters. The average dioptric power is 43-45. Thickness is 0.5 millimeters centrally, and thicker in the periphery to 1 millimeter. Two-thirds of light refraction for vision is performed by the cornea. The refractive power of the corneal structure is about plus-45 diopters.

# Anatomy and Physiology of the Eye

## LAYERS OF THE CORNEA

The outermost layer is the **epithelium**. It is five cell-layers thick and contains the majority of nerve endings, leaving it sensitive to touch and pain. It is similar to skin, with firm attachments within the layer. On the surface are small projections, called microvilli, which act like Velcro to trap the precorneal tear film and smooth out the corneal surface. The normal function is hydrophobic (water-repellent), not allowing fluid to pass through, which helps maintain transparency. There are five to seven layers of cells that regenerate every seven days. This feature allows the epithelium to repair itself after trauma, usually resulting in no scar formation. If oxygen does not get to the epithelium via tears, it can swell, causing corneal edema. If the epithelium gets disrupted, the defects will be apparent when fluorescein dye is applied. Normally the dye stains the area having epithelial defects. Epithelium is adherent to a basement membrane, which is impermeable to water-soluble compounds. It is lipid-soluble, which is an important factor in the manufacturing of eye drops, ensuring the likelihood of absorption.

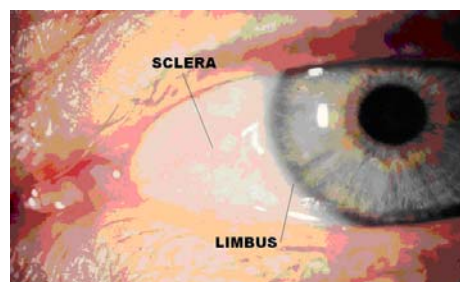
The **Bowman's layer** lies directly under the basement membrane of the epithelium. Consisting of acellular collagen fibrils, this layer cannot regenerate once destroyed. It helps the cornea keep its shape and creates a smooth surface to which epithelial cells may adhere. This creates a barrier effect, preventing fluid and micro-organisms from entering into the stroma. If an injury does occur, a permanent scar usually will form.

The **stroma** makes up 90 percent of the total corneal thickness with its compact layer of collagen fibrils running parallel to the surface to maintain corneal transparency. The cells called keratocytes synthesize the collagen, which is important in wound healing. Corneal nerves enter peripherally in a radial pattern into the stroma. Injury to this area will result in extreme pain from the swelling and stretching of these nerves.

**Descemet's membrane** is on the posterior layer of the stroma and represents the basement membrane of the endothelium. It is a true basement membrane, consisting of collagen and glycoproteins secreted by the endothelium. This is a tough, strong layer resistant to chemicals and trauma, but it can regenerate if damaged. Insults such as trauma, inflammation, age, or a genetic predisposition (guttata) thicken the Descemet's membrane. When the cornea develops an ulcer that destroys all the anterior layers, the only remaining barrier to the intraocular organs is the Descemet's membrane. When this occurs, a descemetocoele forms.

The **endothelium** is the most posterior layer of the cornea. A single layer of flat, polygonal cells with tight junctions, it functions as a permeable membrane to bring in oxygen via aqueous while transporting out fluid and waste products. Acting as a barrier, as well as actively transporting fluid out of the stroma, the endothelium maintains the normal dehydrated state. Over a lifetime, the number of endothelial cells begins to decrease. Endothelial cells don't regenerate, but will slide over and cover the areas of missing cells. As cells die off, the endothelium is unable to maintain an efficient barrier, which may lead to edema and a decrease in visual quality.

The **opaque sclera** forms the posterior five-sixths of the globe. The tissue is avascular and appears white. It is approximately 1 millimeter thick but thins at the equator to approximately 0.6 millimeters. The thinnest part of the sclera is 0.3 millimeters at the insertion point of the rectus muscles. The firmness, strength, and elastic properties of this tissue maintain the shape of the globe (with the intraocular pressure) as well as provide a rigid base for insertion of the extraocular muscles.



*Sclera and limbus*

## Anatomy and Physiology of the Eye

Anteriorly, the sclera forms a junction with the cornea 0.8 millimeters thick, known as the limbus. Covering both the sclera and the conjunctiva is the *episclera*, a loose connective tissue. This is connected to the fascia sheet of *Tenon's capsule* by strands of tissue to the underlying sclera. The episclera has a rich blood supply coming from the anterior ciliary arteries that form a plexus between the limbus and extraocular muscle insertion points. Typically they are located deep in the conjunctiva and are not normally visible. In certain inflammatory responses these vessels become very red and congested.

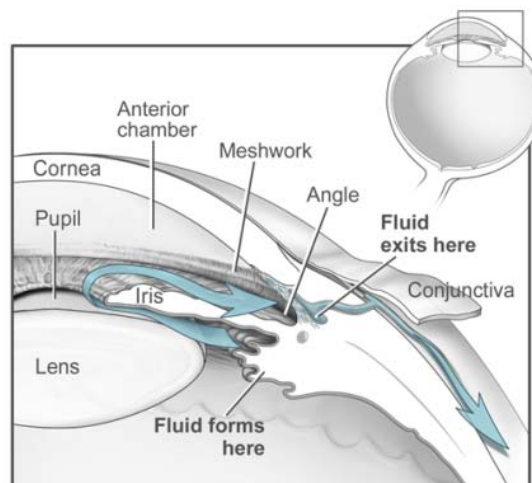
The major structure of the sclera is made up of elastic fibers and dense fibrous tissue. These collagen fibers are arranged in a random order, creating irregular bundles causing the sclera to appear white in color. The corneal fibers are similar but are arranged in a more orderly parallel pattern. The blood supply to the sclera is both from anterior ciliary arteries as well as posteriorly from the long and short posterior ciliary arteries.

Nerve supply is received from ciliary nerves that pierce the sclera from around the optic nerve. The optic nerve perforates the sclera 3 millimeters medially and 1 millimeter above the posterior pole of the globe. This area appears like latticework and is known as the *lamina cribosa*. Central retinal arteries and veins pass through the lamina optic nerve. Because this is weak area, damage can occur when intraocular pressure stays elevated over time. A bulging outward occurs and is visible as increased cupping of the optic nerve head.

The *conjunctiva* is a fibrous membrane that covers the anterior sclera and continues to the back surfaces of the lids to form a conjunctival sac. As above, there are three portions of the conjunctiva: the *bulbar conjunctiva*, which covers the white sclera, the *palpebral conjunctiva*, which covers the backside of the eyelid, and the *fornix*, which is the point at which the bulbar and palpebral conjunctivae meet.

**Ocular media:** The ocular media is the transparent optical surfaces and liquids within the eye, through which light rays pass before reaching the retina. In addition to the cornea above, this includes the anterior chamber, the crystalline lens, and the vitreous.

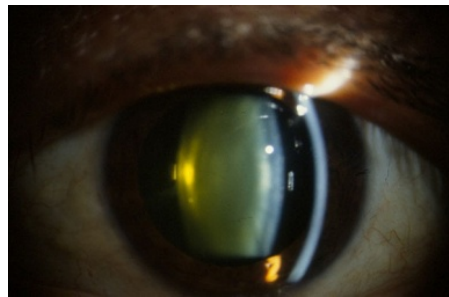
- **Anterior chamber and angles:** The anterior chamber, a fluid filled space, is bounded anteriorly by the cornea and posteriorly by the iris. It is filled with aqueous humor, which is clear, colorless and has a watery consistency (99 percent water). Produced by the ciliary processes at a rate of 2 microliters per minute, the aqueous humor travels from the posterior chamber from behind the iris, through the pupil into the anterior chamber, bathing the cornea and anterior segment. The aqueous humor exits through the angle, which is a drainage structure where the cornea and iris meet. The angle is created by the iris root and peripheral cornea where all these outflow passages lie. The angle is made up of the trabecular meshwork and the canal of Schlemm, then continues through a network of veins draining aqueous out of the eye. Assessment of the angle and structure is performed with a gonioscope. The normal opening of the angle is 30 degrees. Should the angle become narrow, the drainage mechanism may narrow, impeding proper outflow of the aqueous humor. If this angle continues to close to zero degrees, angle-closure glaucoma can result.



Aqueous flow

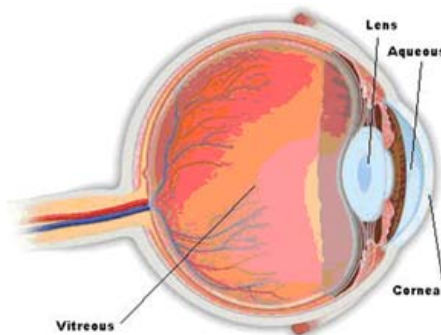
## Anatomy and Physiology of the Eye

- The *crystalline lens* is a biconvex, transparent structure that sits behind the iris and in front of the vitreous. This is the second major refracting structure in the eye, adding approximately 15-20 diopters to the total refractive power of the eye. Transparency is maintained by being avascular, containing no nerves or connective tissue. It is flexible and is suspended in position by zonules that attach it to the ciliary body. The components of the lens are the capsule, epithelium, and lens substance (cortex and nucleus). The *capsule* is an elastic membrane that covers the entire lens, molding the shape of the lens in response to the pull of the zonules during accommodation. This capsule keeps the contents of the lens back by acting as a barrier to vitreous, fluorescein, and bacteria. *Epithelial cells* are cube-shaped and are located beneath the anterior lens capsule. Central fibers transport substances into the lens as well as secrete capsular material. These fibers are made continuously and migrate to the center of the lens, resulting in the lens becoming more rigid and compact. Lens substance makes up the mass of the lens and consists of densely packed cells and fibers, with very little space in between them. The *cortex*, a thick layer of younger cells, contains a high concentration of water, and the *nucleus*, made up of older cells, is located in the center of the lens. The lens contains a high degree of protein. Changes in lens protein cause the lens to lose its elasticity. The lens continues to grow throughout life, mainly in the first two decades and slowing down by the seventh decade. It measures approximately 6.5 millimeters at birth and grows to 10.0 millimeters in diameter as an adult. Thickness can increase to 5 millimeters in an adult as the amount of fibers and cells continue to lie down and become compressed with age. The lens changes shape in order to change the dioptric power of the eye when changing focus from distance objects to near, maintaining a clear image on the retina (accommodation).



Normal adult lens

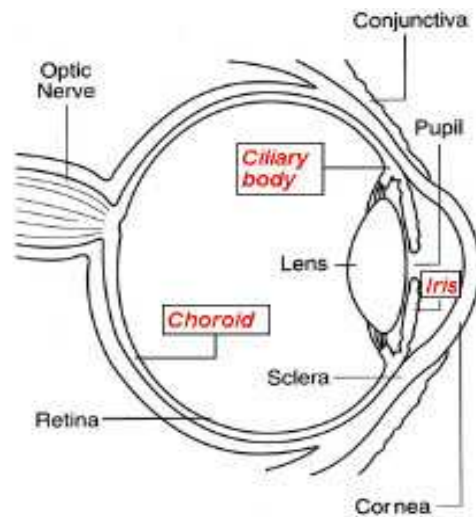
- The *vitreous* makes up the largest volume (approximately 80 percent) of the eye, and is a clear, jelly-like substance. The total volume of vitreous is formed during embryologic development and does not replace itself. Anteriorly, the vitreous face sits behind the posterior lens capsule, and is bounded by the retina posteriorly. The composition of the vitreous is a framework of collagen, mucopolysaccharide, and hyaluronic acid. Attachments of the vitreous are strongest at the ora serrata anteriorly and at the optic nerve and fovea posteriorly. The anterior surface of the vitreous is a condensed hyaloid membrane which prevents vitreous loss during cataract surgery. With age, the consistency of the vitreous becomes liquefied and forms pockets of aqueous. As this process continues, the fibrils of collagen become thick strands. When they become large and pass in front of the visual axis, they are seen as floaters. The vitreous functions to maintain the transparency of the optical media and to provide a constant internal pressure for support of the internal structures of the eye.



Vitreous chamber

## Anatomy and Physiology of the Eye

The **vascular layer** is also known as the uveal tract and consists of three parts, the *ciliary body*, the *iris*, and the *choroid*. It is the middle layer of the eye and is situated between the sclera and retina. As its name implies, this layer consists mostly of blood vessels and capillary nets. As a result of the density of vascularization, chronic ocular disease manifests itself in this area. The function of the vascular layer (uveal tract) is to: 1) produce aqueous humor in the ciliary processes, and 2) alter the shape of the crystalline lens in order for the eye to focus.



*Uveal tract*

- **Ciliary body:** The ciliary body extends from the base of the iris and becomes continuous with the choroid at the ora serrata. It is approximately 6-6.5 millimeters in the anterior-posterior dimension. It is divided into two parts: The *pars plicata* ("folded" or "gathered") produces aqueous in the ciliary processes. These are small, fingerlike projections in the posterior chamber behind the iris. The ciliary processes also are the site of zonules, which connect to the lens. Also found in the *pars plicata* is the ciliary muscle, whose contraction relaxes the zonules, thereby promoting accommodation. The *pars plana* is the most posterior part of the ciliary body. It attaches to the ora serrata of the retina and represents an anatomic landmark for microsurgical instruments to access the posterior segment of the globe.
- The **iris** is the colored part of the eye and forms a diaphragm in front of the crystalline lens. It controls the amount of light transmitted into the eye by changing the size of the pupil. It also prevents excess light from entering the eye and helps form clear images on the retina by preventing peripheral light rays from entering the eye. The two iris muscles control pupil size through the autonomic nervous system by the innervation of the involuntary nervous system. The *dilator muscle*, innervated by the sympathetic nervous system, runs radially in the stroma. When the pupil is dilated, mydriasis occurs. The *sphincter muscle*, innervated by the parasympathetic nervous system, circles the pupillary border. Its function is to decrease the amount of light entering the eye which is called miosis. The iris consists of three layers:
  1. *Anterior:* contains melanocytes (pigment cells) and collagen, with its anterior surface folded into many ridges and crypts
  2. *Middle stromal:* contains fibroblasts, melanocytes, and collagen
  3. *Posterior:* consists of the dilator muscle and pigment epithelium. The stroma, or middle layer, makes up the bulk of the iris and contains blood vessels, nerves, and melanocytes. The number and percentage of melanin granules in the superficial stromal melanocytes determine the color of the iris.

## Anatomy and Physiology of the Eye

- **Choroid:** The primary function of the choroid is to nourish and provide oxygen to the outer layers of the retina, specifically the rods, cones, and retinal pigment epithelium.

The choroid has four layers: the lamina fusca, the stroma, the choriocapillaris, and Bruch's membrane. It is a large, vascular and pigmented tissue that forms the middle coat of the posterior part of the eye and extends from the ora serrata to the optic nerve. The choroid attaches to the sclera by connective tissue strands posteriorly and by many blood vessels and nerves that enter the choroid from the sclera. The retina and choroid share the ophthalmic artery as the major blood supply with three branches of the ophthalmic artery supplying blood to the choroid. Two types of choroidal blood vessels make up the vasculature of the choroid, the choriocapillaris, and large-caliber arteries and veins. Four vortex veins connect together to exit at four major points in the posterior retina, one in each of four quadrants. The semi-permeable *Bruch's membrane* is wedged between the choriocapillaris and on the bottom of the retinal pigment epithelium. A basement membrane allows nutrients to pass through the membrane to the outer layers of the retina but prevents retinal debris from leaving through the pores in the choriocapillaris.

**Nerve layer (receptor cells):** The *retina* is the transparent, innermost layer of the eye and is a direct extension of the brain. Although there are 10 distinct layers of the retina, there are two segments of the retina: the outer retinal pigment epithelium (RPE) and the inner neural retina. The RPE is a single layer of hexagonal cells continuous with the pigment epithelium of the ciliary body at the junction of the ora serrata. This works with Bruch's membrane and the choroid layer to maintain the health of the receptor cells. Breakdown of these cells can cause a build-up of cellular debris.

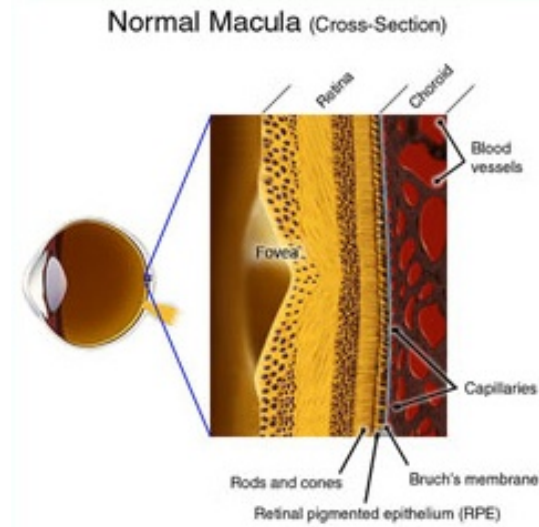
Light must travel through most of the retinal layers in order to stimulate the second layer of photoreceptors, the *rods* and *cones*. Once the photoreceptors change the light signals into electrical impulses, they are amplified and then integrated through the circuits of bipolar, horizontal, amacrine, and ganglion cells. The impulses converge onto bipolar cells and again onto ganglion cells. The axons of ganglion cells merge and exit at the optic disc.



*Layers of the retina*

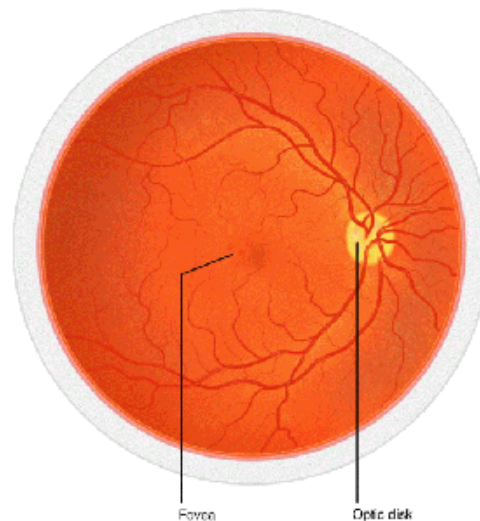
The inner sensory retina is a fine sheet of transparent tissue that varies in thickness from 0.4 millimeters near the optic nerve to 0.15 millimeters near the ora serrata. The macula area receives the sharpest formed images. Its center is slightly depressed to the fovea and lies 3 millimeters temporal to the optic nerve. While there are 126 million receptor cells, the rods outnumber the cones 20 to 1. There are 120 million rods and 6 million cones. *Cones* are densest in the macula, responsible for color and central vision, work best in bright light, capture detail and color, and require direct stimulation. *Rods* are more numerous in the periphery of the retina, function best in dim illumination, detect general form rather than details, and provide background information.

# Anatomy and Physiology of the Eye



*Cross section of the macula*

The point of exit is the optic nerve. There are no photoreceptors in this area, earning it the nickname of “the physiologic blind spot.” Consisting of nerve fibers that carry visual information from the retina to the brain, the optic nerve is housed in the optic disc. This appears yellow in comparison to the orange hue of the retina as a result of the underlying blood supply in the choroid.

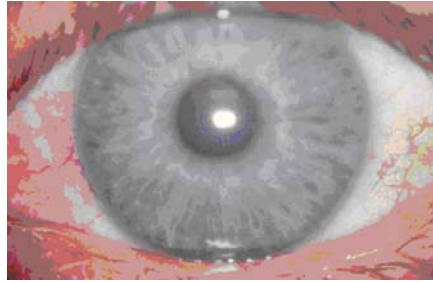


*Fundus*

## PUPILLARY PATHWAYS

The **pupil** is a circular hole in the center of the iris that regulates light entering the eye. It appears black because the tissues inside the eye absorb most of the light entering the pupil. The diameter of the average adult pupil is 3-4 millimeters under average lighting conditions. Pupils are usually proportionally larger in children and smaller in the elderly. The pupillary reflex is most brisk in children. Patients with dense media tend to have a more sluggish reflex than patients of similar age with clear lenses.

# Anatomy and Physiology of the Eye



*Normal iris and pupil*

The function of the pupil is analogous to the shutter of a camera: In darkness, the iris dilator muscle causes the pupil to open, allowing additional light to reach the retina. In bright light, the iris sphincter muscle constricts, causing the pupil to get smaller, limiting the amount of light that reaches the retina. Constriction also occurs during accommodation, one of three components of the near triad of vision (see *below*).

The optic nerve (CN II) is responsible for the *afferent* limb of the pupillary reflex; it senses the incoming light and dilates the pupil. The oculomotor (CN III) nerve is responsible for the *efferent* limb of the pupillary reflex; it drives the muscles that constrict the pupil.

## INNERVATIONAL PATHWAYS

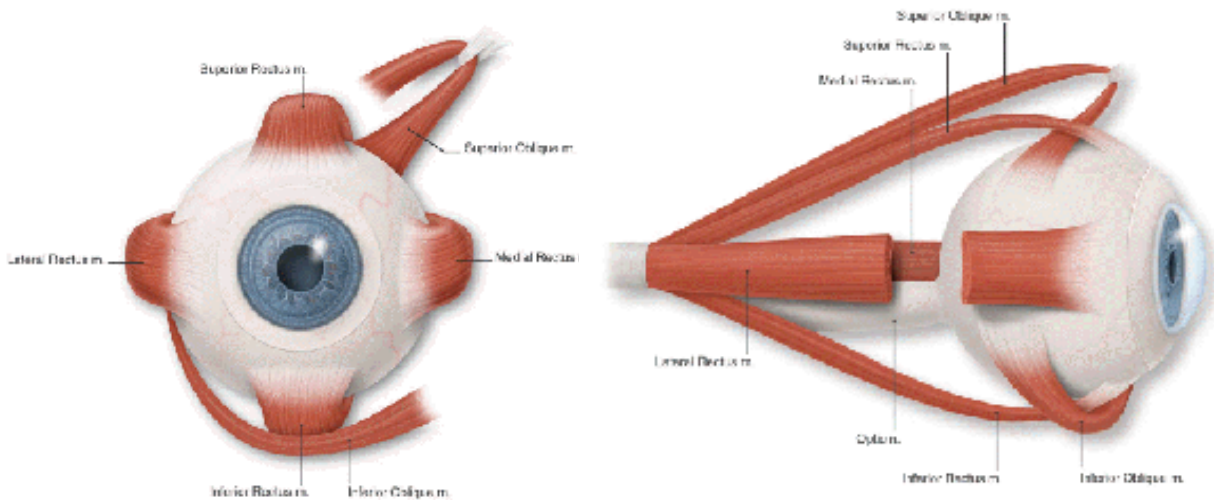
The autonomic nervous system controls organ function so the body can return to its constant state after stimulation from excitement, fear, or activity. Pupillary dilation can occur in response to surprise, fear, and pain. This section will attempt to explain pupillary activity in resting and active states.

- **Parasympathetic:** The light reflex originates at any point when light stimulates the retina. Pupillary light reflex travels down the nerve, chiasm, optic nerve, and nuclei near the thalamus through the superior colliculi terminating at the CN III nucleus for pupillary response as well as accommodation. "Wiring" in the brain links the two eyes together; a reflexive response occurs in one eye when the partner eye is stimulated. *Direct* response occurs when a pupil constricts as light is directed into that eye, compared to the *consensual* response of the opposite eye. When performing pupillary reflex testing, the technician is checking the visual system's response to incoming light, which in turn gets carried to the brain. This is called the *afferent* response. The swinging flashlight tests for a defect in this afferent system. A positive afferent pupillary defect is indicative of a possible conduction problem in the optic nerve.
- **Sympathetic:** The dilator pupillae, innervated by sympathetic nerves from the superior cervical ganglion, cause the pupil to dilate when they contract. These muscles are sometimes referred to as intrinsic eye muscles. The sympathetic nervous system can dilate the pupil in two ways: 1). by the stimulation of the sympathetic nerve in the neck and 2). from an influx of adrenaline (the fright reflex).
- **Near reflex:** The pupils should constrict while looking at a near object. There are two components: convergence reflex (the contraction of the pupil on convergence) and accommodation reflex (the contraction of the pupil on accommodation). Therefore, when patients change from a distant gaze to a near one, the eyes converge, pupils constrict, and the lens gets thicker in order to maintain a clear image on the retina.



# Anatomy and Physiology of the Eye

## EXTRAOCULAR MUSCLES



*Extraocular muscles: front and side views*

By understanding the anatomy of the six extraocular muscles of the eye, it is possible to explain basic eye positions as well as primary and secondary eye movements. Five of the six extraocular muscles originate in the annulus of Zinn. This area is located at the orbital apex and referred to as the *muscle cone*. The sixth muscle originates at the nasal anterior orbital floor. The muscles are organized in an umbrella-like bundle among orbital fat, orbital blood vessels, and nerves. Muscles travel forward through orbital fascia, attaching to the globe by stiff tendons at insertion sites in various locations. Different types of tissues allow for quick bursts of movements (saccades) or slow precise movements (pursuits). Muscles possess a constant state of tonus, or readiness. The muscle plane includes the center of rotation of the globe, muscle insertion, and the origin of the muscles. Extraocular muscles contract back towards their origin, pulling the globe around the center of rotation from the point of insertion. Muscle actions change when the visual axis and muscle plane do not coincide.

### GLOSSARY OF TERMS: EXTRAOCULAR EYE MOVEMENTS

**Visual axis:** A straight line from a distant object of regard to the fovea. It passes through the apex of the cornea, center of the pupil and lens.

**Primary position:** The head is erect, and eyes are looking straight ahead.

**Secondary position:** The gaze is directed up, down, right or left.

**Tertiary position:** Four oblique directions away from primary: up and right, down and right, up and left and lastly, down and left. When the eyes rotate left or right, they travel along the horizontal plane; when they look straight up or down, they travel along the vertical plane. A “torsional plane” is the term to describe eyes that rotate around the visual axis either clockwise or counter clockwise. The action of one or more muscles in these planes controls eye movements.

**Agonist:** The primary mover that controls movement by contracting.

**Antagonist:** Working directly against the agonist, it must relax in order to allow the eye to move in the desired position of action.

**Synergist:** Acts in conjunction with the agonist.

**Yoke muscles:** Muscles in opposite eyes that move in tandem.

# Anatomy and Physiology of the Eye

**Extraocular Muscles:** The following sections discuss the various types of extraocular muscles and their primary and secondary actions:

- **Horizontal recti**

- *Medial rectus:* This is the strongest extraocular muscle because it is the heaviest muscle and has the most anterior insertion on the globe. It arises from the annulus of Zinn and is innervated by CN III.
  - **Action** — adduction: It rotates the eye medially towards the nose. In primary position the muscle plane coincides with the visual axis.
- *Lateral rectus:* Arises from the annulus of Zinn and spans the superior orbital fissure. It is innervated by CN VI.
  - **Action** — abduction: It rotates the eye laterally toward the temple. In primary position the muscle plane coincides with the visual axis.

- **Vertical recti**

- The *superior rectus* arises from the upper part of the annulus of Zinn and travels forward above the globe and superior oblique, but underneath the levator lid muscle. It is innervated by the superior division of the oculomotor Cranial Nerve III.
  - Primary action — elevation: In the primary position, it forms a 23-degree angle with the visual axis. When the eye is abducted, the muscle contracts and goes up.
  - Secondary action — intorsion: When the eye is adducted 67 degrees, the visual axis moves and makes a 90 degree angle with the muscle plane. As it contracts, intorsion occurs with the 12 o'clock position of the eye pointing nasally.
- The *inferior rectus* is the shortest of the recti muscles. It arises at the annulus of Zinn travels downward, then forward, under the globe. It is innervated by CN III.
  - Primary action — depression: This increases as the eye is turned out and is nil when the eye is adducted. The inferior rectus is the only depressor in the abducted position of the eye.
  - Secondary action — extorsion: When the globe is adducted 67 degrees, there is no vertical movement and the 12 o'clock position rotates outward.

- **Oblique Muscles**

- The *superior oblique* is the longest and thinnest eye muscle. It arises at the annulus of Zinn and travels forward along the medial superior side of the orbit, passing through the trochlea, it reflects back to the globe and fans out, inserting on the top of the globe behind the equator underneath the superior rectus. It is innervated by the cranial nerve IV (trochlear)
  - Primary action — intorsion: It moves the eye downwards or laterally or rotates it inwards (i.e. makes twelve o'clock on the cornea move towards the nose).
  - Secondary action — depression: This increases as the eye is adducted. The superior oblique is the only muscle which can depress in the adducted position. Its action is practically nonexistent when the eye is abducted.
- *Inferior oblique:* This is the shortest of the six extraocular muscles and the only muscle that does not originate from the annulus of Zinn. It arises from a rounded tendon in a

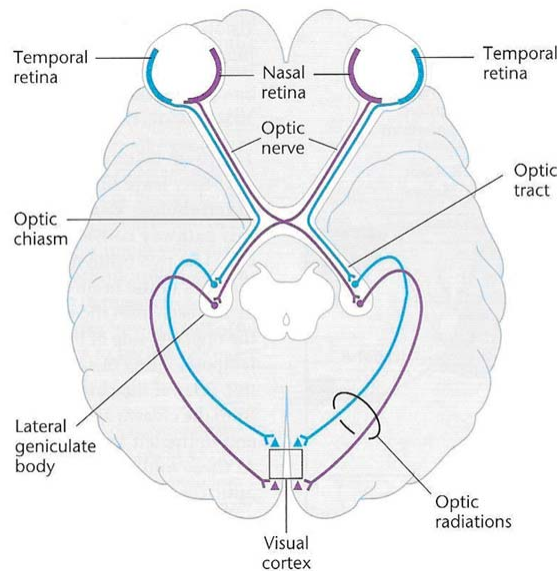
# Anatomy and Physiology of the Eye

depression on orbital floor near orbital rim (maxilla), just behind the orbital margin and lateral to orifice of the naso-lacrimal duct. It is innervated by the inferior division of CN III.

- Primary action — extorsion: The inferior oblique makes the eye look upward or rotates it laterally.
- Secondary action — elevation. This increases as the eye is turned in, and is nil in abduction. The inferior oblique is the only elevator in the adducted position.

## VISUAL PATHWAY

The ability to see is dependent on the clarity of images reaching the brain. Therefore, the optical system must transmit images cleanly without interruption to the retina, which transforms light into electrochemical signals for transmission through the visual pathway to the visual cortex. The visual pathway is made up of axons, which connect the retina to the occipital lobes of the brain at the level of the visual cortex. The pathway starts at the retina, then proceeds from the orbit through the optic disc, along the optic nerve to join with the optic nerve of the other eye at the optic chiasm. Information then passes to the lateral geniculate body, and finally to the occipital cortex. Any disruption of this path from the eye to the brain will result in a visual field defect. Images arrive at the retina inverted (upside down) and also reversed left to right. Objects viewed in space superiorly will be imaged on the inferior retina, while objects viewed to the right in space will be imaged on the left retina.



*Visual pathway*

The **retina** has 10 layers, but only three layers of nerve cells specifically convert light energy into electrochemical signals. Objects are transmitted as light to the photoreceptor (rods and cones) layer of the retina.

Photoreceptors send signals to the optic nerve via the retinal nerve fibers. *Different areas of the retina have varying levels of sensitivity based on the photoreceptor-to-nerve fiber ratio*; there is a 1:1 ratio in the macula. The farther into the retinal periphery, the more photoreceptors there are for every nerve fiber. This decreased sensitivity demands a brighter light to capture the image. There are no photoreceptors at the optic disc (termed “the physiologic blind spot”); therefore, no light can be detected.

The axons of the ganglion cells create the *retinal nerve fiber layer*. They pass through the optic disc to become the optic nerve. The nerve fiber layer is distributed across the retina in a very specific pattern as it moves toward the optic disc. The nerve fiber layer that originates in the superior retina (which

## Anatomy and Physiology of the Eye

corresponds to inferior visual field) enters the disc superiorly. Similarly, the nerve fiber layer that originates in the inferior retina (which corresponds to superior visual field) enters the optic disc inferiorly.

The *papillomacular bundle* consists of nerve fibers from the macula, fovea, and areas temporal to the disc. These fibers enter the disc temporally, forming a thick rim. This line of demarcation extends from the periphery temporally to the fovea. Nasal fibers enter the disc in a radial pattern creating a fan-shaped temporal defect. The nerve fibers exit the disc through the lamina cribosa which is made up of a sieve of holes in the sclera. Optic nerves carry each eye's signal back to brain.

The *optic chiasm* is the area of the visual pathway where the optic nerves of each eye join. Optic nerves meet near the center of the skull at the optic chiasm, just above the pituitary gland. Nerve fibers that originate nasal to the fovea cross to opposite half of the brain, while fibers that originate temporally continue along the pathway without crossing. Visual fields now split into two distinctive halves. Fibers from the *nasal retina* (which sees the *temporal* visual field) cross to opposite side of brain. Fibers from the *temporal retina* (which sees the *nasal* visual field) do not cross but stay on the same side of the brain. Ten percent of nerve fibers that represent the entire retina will leave the optic tract and terminate in the brainstem. These fibers are associated with pupillary function. The remaining 90 percent of the fibers travel to the lateral geniculate body.

**Lateral geniculate body:** Axons leave the optic tract and synapse with cells that ultimately are going to the occipital cortex. As the axons leave the lateral geniculate body, they fan out into optic radiations. As the fibers leave, they travel to the same side in the occipital lobe. Some of the exiting inferior fibers bend around the temporal horn of the lateral ventricle into the temporal lobe before terminating into the inferior portion of the occipital lobe. These fibers represent Meyer's loop and correspond to the inferior retina of both eyes.

**Visual cortex (V1 or Brodmann's area):** Located in the occipital lobe, pairs of retinal fibers project onto the same location in the calcarine fissure. The fissure has three zones; posterior macula area, binocular peripheral area, and the monocular peripheral area. The most posterior tip of the brain contains information from the central 5 degrees of the macular field. The visual cortex has a map of the retina's surface. More cortical neurons are devoted to fovea than the periphery of the retina. As the fovea has only cones, they are widely mapped on the surface of the cortex.

## CONCLUSION

Having a detailed, clinical understanding of the anatomy and physiology of the eye — what makes up the eye and how it works — is critical for a practice to triage patients accurately and seamlessly with reality-based confidence in their ability to provide quality care and excellent outcomes.

# Anatomy and Physiology of the Eye

## COURSE EXAMINATION

- Which of the following is hydrophobic?
  - Epithelium
  - Bowman's membrane
  - Stroma
  - Endothelium
  - a and d
- The primary lifting of the upper lid is performed by \_\_\_\_\_.
  - Contraction of dilator muscle.
  - The levator muscle.
  - Contraction of the sphincter muscle.
  - Relaxation of the ciliary muscle.
  - Both a and c.
- The structure of the eye that continues to grow throughout life is the \_\_\_\_\_.
  - Cornea.
  - Iris.
  - Lens.
  - Vitreous.
  - Retina.
- The functions of the orbit are to provide protection, support, and attachment of the cranial nerves.
  - True
  - False
- The junction between the cornea and sclera is the \_\_\_\_\_.
  - Limbus.
  - Conjunctiva.
  - Stroma.
  - Choroid.
  - None of the above.
- Name the anatomical structure that gives shape and rigidity to the eyelid.
  - Obicularis
  - Levator
  - Orbital septum
  - Palpebral conjunctiva
  - Tarsal plate
- The extraocular muscle that does NOT originate at the annulus of Zinn is the \_\_\_\_\_.
  - Medial tectus.
  - Lateral tectus.
  - Superior oblique.
  - Inferior rectus.
  - Inferior oblique.
- The cranial nerve responsible for AFFERENT pupillary reflex is:
  - CN I
  - CN II
  - CN III
  - CN IV
  - CN V

## Anatomy and Physiology of the Eye

9. The Visual Pathway begins at the \_\_\_\_\_.  
a. Cornea.  
b. Iris.  
c. Lens.  
d. Optic nerve.  
e. Retina.
10. Accommodation and aqueous production are a function of the:  
a. Secretory System  
b. Ciliary Body  
c. Excretory System  
d. Lens  
e. Zonules
11. The aqueous humor exits the anterior chamber through the drainage structure located in the \_\_\_\_\_.  
a. Cornea.  
b. Iris.  
c. Angle  
d. Sclera
12. The structure which does NOT make up transparent ocular media is the \_\_\_\_\_.  
a. Cornea.  
b. Lens.  
c. Aqueous.  
d. Iris.  
e. Vitreous.
13. The posterior chamber is:  
a. Between the iris and in front of vitreous face.  
b. Behind the cornea in front of the iris.  
c. Behind the vitreous in front of the retina.  
d. In front of endothelium and behind the epithelium.  
e. Behind the iris.
14. The main depressor of the eyelids is:  
a. Levator  
b. Mueller's muscle  
c. Inferior rectus  
d. Obicularis  
e. Superior oblique
15. The area susceptible to blunt trauma of the orbit is:  
a. Orbital foramen  
b. Orbital roof  
c. Orbital floor  
d. Orbital septum  
e. Orbital fissure
16. The area in the retina that represents the physiologic blind spot is:  
a. Rods  
b. Macula  
c. Fovea  
d. Cones  
e. Optic nerve

## Anatomy and Physiology of the Eye

17. The temporal fibers of the optic nerve do not cross, while nasal fibers do cross at the optic chiasm.
- True
  - False
18. The vascular layer of the eye consists of the \_\_\_\_\_.
- Ciliary body.
  - Iris.
  - Choroid.
  - All of the above.
  - None of the above.
19. Which of the following is NOT a layer of the cornea?
- Epithelium
  - Endothelium
  - Bowman's layer
  - Broadman's area
  - Descemet's membrane
20. The eyeball consists of which of the following layers?
- Fibrous layer
  - Oily layer
  - Vascular layer
  - Nerve layer
  - All of the above
  - a, c, and d