

Epidermolysis bullosa in a small for gestational age preterm male neonate with two affected siblings: A case report

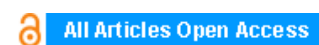
Swathi Chacham, Jakkampudi Nagasravani, Uppin Narayan Reddy, Jillalla Narsing Rao, S. Pratap Rao, Kumar A. S.

ABSTRACT


Introduction: Epidermolysis bullosa is a rare group of hereditary disorders, which are characterized by blistering of the skin and mucosa due to little or no apparent trauma. The severity can range from mild, localized skin blisters to generalized, systemic life-threatening disease and the treatment is mainly supportive. Dystrophic type of epidermolysis bullosa is one of the rarer forms. Skin fragility often leads to secondary skin infections and in turn generalized infection which can be lethal. Hence, the major challenge encountered in the care of a neonate with epidermolysis bullosa is optimum skin care and expert nursing care. A preterm, small for gestational age (SGA) neonate, has immature skin physiologically, which is a portal for systemic infection when compared to a term appropriate for gestational age neonate. The presence of blistering lesions in a preterm, SGA neonate further challenges the management.

Case Report: We report a preterm, low birth weight (small for gestational age) male neonate, who had extensive bullous lesions and dystrophic nails in the first week of life. These lesions healed by scarring leading to stiffness of underlying joints and were complicated by secondary infection. There was history of consanguinity and previous two siblings also had similar lesions with contractures.

Conclusion: A preterm male small for gestational age neonate born of consanguineous marriage, with the history of cutaneous bullous lesions in two siblings, presented with extensive bullous lesions and dystrophic nails, suggestive of dystrophic epidermolysis bullosa.



International Journal of Case Reports and Images (IJCRI)



International Journal of Case Reports and Images (IJCRI) is an international, peer reviewed, monthly, open access, online journal, publishing high-quality, articles in all areas of basic medical sciences and clinical specialties.

Aim of IJCRI is to encourage the publication of new information by providing a platform for reporting of unique, unusual and rare cases which enhance understanding of disease process, its diagnosis, management and clinico-pathologic correlations.

IJCRI publishes Review Articles, Case Series, Case Reports, Case in Images, Clinical Images and Letters to Editor.

Website: www.ijcasereportsandimages.com

CASE REPORT

OPEN ACCESS

Epidermolysis bullosa in a small for gestational age preterm male neonate with two affected siblings: A case report

Swathi Chacham, Jakkampudi Nagasravani, Uppin Narayan Reddy, Jillalla Narsing Rao, S. Pratap Rao, Kumar A. S.

ABSTRACT

Introduction: Epidermolysis bullosa is a rare group of hereditary disorders, which are characterized by blistering of the skin and mucosa due to little or no apparent trauma. The severity can range from mild, localized skin

blisters to generalized, systemic life-threatening disease and the treatment is mainly supportive. Dystrophic type of epidermolysis bullosa is one of the rarer forms. Skin fragility often leads to secondary skin infections and in turn generalized infection which can be lethal. Hence, the major challenge encountered in the care of a neonate with epidermolysis bullosa is optimum skin care and expert nursing care. A preterm, small for gestational age (SGA) neonate, has immature skin physiologically, which is a portal for systemic infection when compared to a term appropriate for gestational age neonate. The presence of blistering lesions in a preterm, SGA neonate further challenges the management. **Case Report:** We report a preterm, low birth weight (small for gestational age) male neonate, who had extensive bullous lesions and dystrophic nails in the first week of life. These lesions healed by scarring leading to stiffness of underlying joints and were complicated by secondary infection. There was history of consanguinity and previous two siblings also had similar lesions with contractures. **Conclusion:** A preterm male small for gestational age neonate born of consanguineous marriage, with the history of cutaneous bullous lesions in two siblings, presented with extensive bullous lesions and dystrophic nails, suggestive of dystrophic epidermolysis bullosa.

Keywords: Blistering, Dystrophic, Neonate, Epidermolysis bullosa, Low birth weight, Preterm, Small for gestational age (SGA), Infant

Swathi Chacham¹, Jakkampudi Nagasravani², Uppin Narayan Reddy³, Jillalla Narsing Rao⁴, S. Pratap Rao⁵, Kumar AS⁶

Affiliations: ¹MD Pediatrics, DM Neonatology (from Post Graduate Institute of Medical Education and Research, Chandigarh, India), Assistant Professor, Department of Pediatrics, Princess Esra Hospital, Deccan College of Medical Sciences, Hyderabad, Andhra Pradesh, India; ²MBBS, (MD, Pediatrics), Junior Resident Doctor, Department of Pediatrics Princess Esra Hospital, Deccan College of Medical Sciences, Hyderabad, Andhra Pradesh, India; ³MD Pediatrics, Professor and Head, Department of Pediatrics Princess Esra Hospital, Deccan College of Medical Sciences, Hyderabad, Andhra Pradesh, India; ⁴MD Pediatrics, Professor, Department of Pediatrics, Princess Esra Hospital, Deccan College of Medical Sciences, Hyderabad, Andhra Pradesh, India; ⁵MD Pediatrics, Professor, Department of Pediatrics, Princess Esra Hospital, Deccan College of Medical Sciences, Hyderabad, Andhra Pradesh, India; ⁶MD Dermatology (From All India Institute Of Medical Sciences, New Delhi), Professor and Head, Department of Dermatology, Princess Esra Hospital, Deccan College of Medical Sciences, Hyderabad, Andhra Pradesh, India.

Corresponding Author: Swathi Chacham, MD, DM, (Neonatology), Princess Esra Hospital, Deccan College of Medical Sciences, Hyderabad, Andhra Pradesh, India; Residence (Mailing Address): Flat No.405, Kalyani Sridhar Plaza, House No. 2-2-1130/4, New Nallakunta, Hyderabad, Andhra Pradesh, India. Postal Code: 500044; Ph: +919849447306; Email: swathi.m.lahiri@gmail.com

Received: 19 May 2014
Accepted: 24 June 2014
Published: 01 October 2014

How to cite this article

Chacham S, Nagasravani J, Reddy UN, Rao JN, Rao SP, Kumar AS. Epidermolysis bullosa in a small for gestational age preterm male neonate with two affected siblings: A case report. Int J Case Rep Images 2014;5(10):691–694.

doi:10.5348/ijcri-2014122-CR-10433

INTRODUCTION

Epidermolysis bullosa (EB) is an intractable, rare and often lethal skin condition. It is characterized by the development of vesicles and bullae either spontaneously or as a result of minimal insignificant trauma. Epidermolysis bullosa is due to a congenital defect in the skin structure and is often hereditary. There are three major types of EB described, namely: simplex, junctional and dystrophic [1]. Reported prevalence of EB varies from 10–20 cases per 1 million live births as per various EB registries [2–5]. A preterm, small for gestational age (SGA) neonate, has immature skin physiologically, which is a portal for systemic infection when compared to a term appropriate for gestational age neonate [6].

CASE REPORT

A 36-week male neonate, weighing 1800 grams was born to a gravida four mother by emergency cesarean section for absent end diastolic flow in antenatal Doppler ultrasound. The neonate had normal extra uterine transition with normal APGAR scores. The birth weight was less than third centile, hence it was a SGA neonate. The neonate had mild respiratory distress requiring supplemental oxygen and antibiotics. Sepsis screen was negative and initial blood glucose levels were low. Blood culture was sterile and the chest X-ray showed features of transient tachypnea of newborn. Respiratory distress subsided by 48 hours and baby developed mild jaundice requiring phototherapy. Feeds were started on second day of life and full feeds were established by fourth day of life. There was history of second degree consanguinity and history of bullous lesions in two previous siblings in the neonatal period. They succumbed to death at second and seven months of life, respectively due to repeated skin and respiratory infections.

The neonate developed fluid filled bullae over both elbows and gluteal region on the fourth day of life. Basic interventions such as intravenous cannulation provoked blistering. The bullous lesions subsequently spread all over the body and healed by scarring (Figure 1A). However, there was no mucosal involvement. Hence, EB was diagnosed and the dystrophic variety was considered in view of extensive scarring and dystrophic nails (Figure 1B). The neonate was discharged with topical emollients, skin protective measures and nutritional supplements for catch up growth. The infant had good weight gain, and was thriving well till four months, despite frequent blistering episodes and scarring. Frequent scarring had lead to stiffening of fingers and toes. Though the skin biopsy could not be performed due to the financial

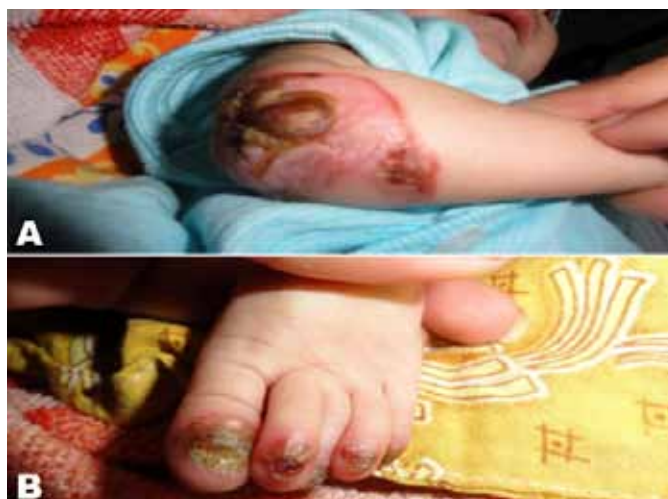

Figure 1 (A, B): Clinical image showing dystrophic toe nails and scarring and disfigurement over the right elbow.

constraints, clinically dystrophic EB was considered in view of stiffening of fingers and toes in the index case and contractures in the previous siblings. Subsequently, the infant had secondary skin infection which was associated with generalized sepsis and pneumonia. Sepsis screen was positive and antibiotics were started. However, worsening pneumonia had lead to respiratory failure and death.

DISCUSSION

Epidermolysis bullosa is a mucocutaneous blistering disorder of hereditary nature. Blistering lesions are provoked by little or no apparent trauma. It has a wide spectrum of manifestations as well as complications. Severity ranges from localized skin blisters to neonatal mortality [2]. Three major phenotypes have been described depending on the level of cleavage of the basement membrane at dermoepidermal junction, namely simplex, junctional and dystrophic [1, 7]. The level of separation in EB simplex is intraepidermal and is at lamina densa in junctional EB. However, in dystrophic EB the separation is below the basement membrane [2, 8]. Each of these three main phenotypes have both autosomal dominant and autosomal recessive form of inheritance. Epidermolysis bullosa simplex has predominantly autosomal dominant inheritance, while the mode of inheritance is autosomal recessive in majority of junctional EB [7, 8]. The wide range of genetic abnormalities occur in various types of EB. K5 or K14 gene mutations result in bullous formation by disrupting the basal cells in dominant EB simplex as well as some forms of recessive EB simplex. While, type XVII collagen, laminin 5 and $\alpha 6$, $\beta 4$ integrin gene mutations are seen in junctional EB and dystrophic variant is linked with type VII collagen gene abnormalities [7]. The index

neonate had developed the lesions in the first week of life, suggestive of autosomal recessive inheritance. Along with the history of consanguinity and similar lesions in siblings in the neonatal period, the recessive mode of inheritance was further confirmed. Though the skin biopsy is confirmatory to differentiate various forms of epidermolysis bullosa, deep scarring with contractures is peculiar to dystrophic EB. The index case had stiffening of fingers and toes, though the neonate did not survive longer to develop contractures. However, there was history of contractures in the previous siblings. The clinical severity of the different forms of EB varies widely and internal organ involvement can occur [4].

The incidence and prevalence rates expressed as number of cases per 1 million live births, for EB simplex: 10.75, junctional EB: 2.04, dystrophic EB dominant type: 2.86 and recessive dystrophic EB: 2.04. Epidermolysis bullosa has no gender, geographical or racial preponderance. Epidermolysis bullosa simplex is the most prevalent phenotype, where as autosomal recessive dystrophic and junctional EB are rare [2–5]. In view of blisters affecting the whole body with scarring and disfigurement, recessive type of dystrophic epidermolysis bullosa (Hallopeau-Siemens type) was considered in the index case [9].

A preterm, SGA neonate has immature skin physiologically, which is a portal for systemic infection when compared to a term appropriate for gestational age neonate. The need for invasive monitoring and invasive procedures hampers the skin integrity. The presence of blistering lesions in a preterm, SGA neonate further challenges the management.

Currently, there is no definitive and curative treatment for EB. Hence, the mainstay of treatment is symptomatic, supportive and preventive [10]. The major challenge encountered in the care of a neonate with EB is optimum skin care and expert nursing care more so, with a preterm, low birth weight neonate who undergoes many invasive skin procedures as in the index case [6].

The key measures that need to be taken in neonates and children with EB are preventing trauma induced blisters and avoiding unnecessary antibiotics. These can be achieved by nursing the infants on soft foam pads and restricting the use of topical antimicrobials, which were implemented in the index case [10]. The lesions were cleaned with sterile normal saline and covered with non-adhesive dressings. Topical antimicrobials were avoided, unless needed, to prevent the emergence of resistant bacteria. Soft, non-adhesive dressing materials soaked with emollients such as vaseline (which are preferred) were used as a preventive measure. Parents were counseled and psychological support was given to them, which plays a significant role in the care of these neonates [10]. Adequate nutritional support is necessary for optimum growth and development and to aid in wound healing, more so in a preterm, SGA neonate who is challenged nutritionally otherwise. Genetic counseling is required for families of affected children along with

prenatal diagnosis (using molecular techniques) [10]. Most common cause of death is secondary bacterial infection resulting from frequent blisters. Similarly, index case developed skin infection which lead to pneumonia, respiratory failure and death subsequently.

CONCLUSION

A preterm male small for gestational age neonate born of consanguineous marriage, presented with extensive bullous lesions and dystrophic nails, suggestive of epidermolysis bullosa. The lesions were complicated by scarring, which lead to stiffening of fingers. Similar lesions in the two previous siblings along with contractures suggests dystrophic variant of epidermolysis bullosa.

Acknowledgements

Thank Mrs. Shashi vadana for helping with graphics and Dr. Taha, Dr. Muzammil Hassan and Muzahid for helping with drafting.

Abbreviations

APGAR, BM, (Basement membrane), EB, (epidermolysis bullosa), SGA, (small for gestational age).

Author Contributions

Swathi Chacham – Substantial contributions to conception and design, Acquisition of data, Analysis and interpretation of data, Drafting the article, Revising it critically for important intellectual content, Final approval of the version to be published

Jakkampudi Nagasravani – Substantial contributions to conception and design, Acquisition of data, Analysis and interpretation of data, Drafting the article, Revising it critically for important intellectual content, Final approval of the version to be published

Uppin Narayan Reddy – Substantial contributions to conception and design, Acquisition of data, Analysis and interpretation of data, Revising it critically for important intellectual content, Final approval of the version to be published

Jillalla Narsing Rao – Substantial contributions to conception and design, Acquisition of data, Analysis and interpretation of data, Revising it critically for important intellectual content, Final approval of the version to be published

S. Pratap Rao – Substantial contributions to conception and design, Acquisition of data, Analysis and interpretation of data, Revising it critically for important intellectual content, Final approval of the version to be published

Kumar A. S. – Substantial contributions to conception and design, Acquisition of data, Analysis and interpretation of data, Revising it critically for important intellectual content, Final approval of the version to be published

Guarantor

The corresponding author is the guarantor of submission.

Conflict of Interest

Authors declare no conflict of interest.

Copyright

© 2014 Swathi Chacham et al. This article is distributed under the terms of Creative Commons Attribution License which permits unrestricted use, distribution and reproduction in any medium provided the original author(s) and original publisher are properly credited. Please see the copyright policy on the journal website for more information.

REFERENCES

1. Pearson RW. Studies on the pathogenesis of epidermolysis bullosa. *J Invest Dermatol* 1962 Dec;39:551–75.
2. Fine JD, Johnson LB, Suchindran C, Moshell A, Gedde-Dahl T Jr. The Epidemiology of Inherited Epidermolysis Bullosa: Findings in the US, Canadian and Europeanstudypopulations, and the findings of the national epidermolysis bullosa registry. Baltimore: John's Hopkins university press 1999:101–13.
3. Kho YC, Rhodes LM, Robertson SJ, et al. Epidemiology of epidermolysis bullosa in the antipodes: The Australasian epidermolysis bullosa registry with a focus on herlitz junctional epidermolysis bullosa. *Arch Dermatol* 2010 Jun;146(6):635–40.
4. McKenna KE, Walsh MY, Bingham EA. Epidermolysis bullosa in Northern Ireland. *Br J Dermatol* 1992 Oct;127(4):318–21.
5. Browne F Heagerty AHM, Martinez A, Mellerio J, Moss C. The epidemiology of epidermolysis bullosa in the UK. A 9- year study. *Br J Dermatol* 2011;165.
6. Korner A, Dinten-Schmid B, Stoffel L, Hirter K, Kappeli S. Skin care and skin protection in preterm babies. *Pflege* 2009 Aug;22(4):266-76. [Article in German].
7. Mitsuhashi Y, Hashimoto I. Genetic abnormalities and clinical classification of epidermolysis bullosa. *Arch Dermatol Res* 2003 Apr;295 Suppl 1:S29–33.
8. Pulkkinen L, Uitto J. Mutation analysis and molecular genetics of epidermolysis bullosa. *Matrix Biol* 1999 Feb;18(1):29–42.
9. Sarkar R, Bansal S, Garg VK. Epidermolysis bullosa: Where do we stand? *Indian J Dermatol Venereol Leprol* 2011 Jul-Aug;77(4):431–8.
10. Purushotham DR, Sunil B, Aadarsh E, Rajanish KV, Tamilselvan, Karthik Arigela. Epiermolysis bullosa in newborn: A case report. *Scholars journal of applied medical sciences*2014;2(1B):149–51.

Access full text article on
other devices



Access PDF of article on
other devices



Edorium Journals: An introduction

Edorium Journals Team

About Edorium Journals

Edorium Journals is a publisher of high-quality, open access, international scholarly journals covering subjects in basic sciences and clinical specialties and subspecialties.

Invitation for article submission

We sincerely invite you to submit your valuable research for publication to Edorium Journals.

But why should you publish with Edorium Journals?

In less than 10 words - we give you what no one does.

Vision of being the best

We have the vision of making our journals the best and the most authoritative journals in their respective specialties. We are working towards this goal every day of every week of every month of every year.

Exceptional services

We care for you, your work and your time. Our efficient, personalized and courteous services are a testimony to this.

Editorial Review

All manuscripts submitted to Edorium Journals undergo pre-processing review, first editorial review, peer review, second editorial review and finally third editorial review.

Peer Review

All manuscripts submitted to Edorium Journals undergo anonymous, double-blind, external peer review.

Early View version

Early View version of your manuscript will be published in the journal within 72 hours of final acceptance.

Manuscript status

From submission to publication of your article you will get regular updates (minimum six times) about status of your manuscripts directly in your email.

Our Commitment

Six weeks

You will get first decision on your manuscript within six weeks (42 days) of submission. If we fail to honor this by even one day, we will publish your manuscript free of charge.

Four weeks

After we receive page proofs, your manuscript will be published in the journal within four weeks (31 days). If we fail to honor this by even one day, we will publish your manuscript free of charge and refund you the full article publication charges you paid for your manuscript.

Mentored Review Articles (MRA)

Our academic program "Mentored Review Article" (MRA) gives you a unique opportunity to publish papers under mentorship of international faculty. These articles are published free of charges.

Favored Author program

One email is all it takes to become our favored author. You will not only get fee waivers but also get information and insights about scholarly publishing.

Institutional Membership program

Join our Institutional Memberships program and help scholars from your institute make their research accessible to all and save thousands of dollars in fees make their research accessible to all.

Our presence

We have some of the best designed publication formats. Our websites are very user friendly and enable you to do your work very easily with no hassle.

Something more...

We request you to have a look at our website to know more about us and our services.

We welcome you to interact with us, share with us, join us and of course publish with us.



Edorium Journals: On Web



Browse Journals

CONNECT WITH US

