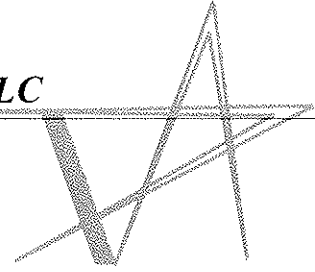


COMMONWEALTH ENVIRONMENTAL SERVICES, LLC

"A Native American - Woman Owned Company"



Gary Vander Boegh, Vice President
Commonwealth Environmental Services, LLC
4645 Village Square Drive, St. F
Paducah, Kentucky 42001
Telephone: (270) 450-0850
Facsimile: (270) 450-0858

September 10, 2010

U. S. Department of Labor,
Frances Perkins Building, 200 Constitution Ave., NW
Room S-2018
Washington, DC 20210
Facsimile (904) 357-4704

Attention: Jim Bibeault & Madam Secretary Hilda Solis

Employee: Dolores J. Allen
File Number: 407409972

Dear Mr. Bibeault and Ms Solis,

As "Authorized Representative" (AR) for employee/ claimant Dolores J. Allen I hereby submit the attached EE-1 form for Chronic Beryllium Disease (CBD) based on statutory requirements 42 USC § 73841 (13) (B) as follows:

- (B) For diagnoses before January 1, 1993, the presence of—
- (i) **occupational or environmental history**, or epidemiologic evidence of beryllium exposure; and
 - (iii) **any three of the following criteria:**
 - (I) Characteristic chest radiographic (or computed tomography (CT)) abnormalities.**
 - (II) Restrictive or obstructive lung physiology testing or diffusing lung capacity defect.**
 - (III) Lung pathology consistent with chronic beryllium disease.
 - (IV) Clinical course consistent with a chronic respiratory disorder.**
 - (V) Immunologic tests showing beryllium sensitivity (skin patch test or beryllium blood test preferred).

The Department of Labor has further stated, "For beryllium disease prior to January 1, 1993, a specific diagnosis of CBD IS NOT REQUIRED (emphasis added.)"....

Per Chapter 2-700.4 (September 2004) of the Federal (EEOICPA) Procedure Manual, "To determine whether to use the Pre or Post 1993 CBD criteria, the medical evidence must demonstrate that the employee was either treated for, tested or diagnosed with a chronic respiratory disorder. If the earliest dated document is prior to January 1, 1993, the pre-1993 CBD criteria may be used. Once it is established that the employee had a chronic respiratory disorder prior to 1993, the CE is not limited to use of medical reports prior to 1993 to meet the three of five criteria."

The Paducah Gaseous Diffusion Plant was a DOE facility from 1952 to July 28, 1998 and July 29, 1998 to present (remediation) where radioactive and beryllium materials were present, according to the Department of Energy Office of Worker Advocacy Facility List (<http://www.hss.energy.gov/HealthSafety/FWSP/Advocacy/faclist/findfacility.cfm>).

(Excerpt)

DOCKET NUMBER: 57973-2005

Decision Date: January 7, 2005

NOTICE OF FINAL DECISION

This is the decision of the Final Adjudication Branch concerning your claim for compensation under Part B of the Energy Employees Occupational Illness Compensation Program Act of 2000, as amended, 42 U.S.C. § 7384 *et seq.* (EEOICPA or the Act). This decision affirms the recommended acceptance issued on November 30, 2004.

STATEMENT OF THE CASE

On May 28, 2004, you filed a claim for survivor benefits, as the widow of [Employee], Form EE-2, under Part B of the EEOICPA. You identified "breathing problems" and chronic beryllium disease (CBD) as the claimed conditions. You also filed a Form EE-3 indicating that your husband was employed by F.H. McGraw at the Paducah Gaseous Diffusion Plant in Paducah, Kentucky from 1951 to "I don't remember."

The Department of Energy (DOE) was unable to verify employment, however, they did confirm that F.H. McGraw held a number of contracts, during this time, at the Paducah Site. You submitted Social Security records indicating that your husband was employed by F.H. McGraw from the fourth quarter of 1951 to the third quarter of 1954. Social Security reported maximum reportable earnings (\$3600.00) for 1952, 1953 and 1954. The DOE also submitted a "Personnel Clearance Master Card" from F.H. McGraw and Company that indicated [Employee] was terminated on December 17, 1954 due to a reduction in force; this notice also indicated that a Q Clearance was granted on February 14, 1952.[1]

Based upon the DOE response that F.H. McGraw held a number of contracts from 1951 to 1954 and the security Q clearance notification, the district concluded that the DOE had a business or contractual arrangement with F.H. McGraw. The district office further concluded that your husband worked with F.H. McGraw at the Paducah Gaseous Diffusion Plant for at least one day on December 17, 1954 based upon the reduction in force notice.[2]

The death certificate submitted showed that [Employee] died on October 12, 1999, and the immediate cause of death as congestive heart disease. The death certificate indicated that the surviving spouse was [Claimant]. You submitted a marriage certificate showing that [Employee] and [Claimant] were married on March 23, 1940.

You submitted a medical report dated February 23, 1991, from Lowell F. Roberts, M.D., which indicates a history of chronic obstructive pulmonary disease (COPD), shortness of breath, and dyspnea. A February 23, 1991 X-ray report, from D.R. Hatfield, M.D., indicates a diagnosis of COPD. A February 25, 1991 CT-scan, from Barry F. Riggs, M.D., indicates abnormal nodular densities of the right lower lobe and a diagnosis of COPD. A February 26, 1991 medical report from M.Y. Jarfar, M.D. indicated that pulmonary function tests showed mild obstructive defects and mild diffusing lung capacity defects. You also submitted an X-ray report dated September 6, 1994, from Robert A. Garneau, M.D., that indicated diagnoses of COPD and Interstitial Fibrosis. A November 27, 1994 medical report from David Saxon, M.D., indicated findings of rales and wheezing. A December 2, 1994 medical report from Dr. Saxon, indicates hypoxemia to the left lower lung. A December 2, 1994 medical report from Lowell F. Roberts, M.D., indicated diagnoses of shortness of breath, congestive heart failure, dyspnea and cough, and rales in the lung base. An August 13, 1995 X-ray report from Charles Bea, M.D., indicates a diagnoses of bibasilar infiltrates. A December 30, 1996 X-ray report from Sharron Butler, M.D., indicates an increase of lung markings since the September 14, 1992 study. In the March 1, 1998 X-ray report from Dr. Butler diagnoses of "advanced chronic lung changes, mild interstitial prominence diffusely, and patch density of the posterior right lung" are indicated. An August 19, 1998 CT-scan from James D. Van Hoose, indicates diagnoses of pleural thickening and pulmonary calcifications. An August 6, 1999 pulmonary function test from William Culberson, M.D. indicates a diagnosis of moderately severe restrictive disease. An October 12, 1999 discharge summary from Eric B. Scowden, M.D. indicates diagnoses of progressive shortness of breath, congestive heart disease, COPD, and history of right-sided empyema complicating pneumonia necessitating prolonged chest tube drainage with a continued open sinus tract." Based upon these reports the district office concluded that you had CBD prior to January 1, 1993.[3]

On November 30, 2004, the district office issued a recommended decision concluding that your husband was a covered beryllium employee, that he was exposed to beryllium, and that he had symptoms and a clinical history similar to CBD prior to January 1, 1993. They further concluded that you are entitled to compensation in the amount of \$150,000 pursuant to § 7384s of the EEOICPA.

Section 30.316(a) of the EEOICPA implementing regulations provides that, "if the claimant does not file a written statement that objects to the recommended decision and/or requests a hearing within the period of time allotted in 20 C.F.R. § 30.310, or if the claimant waives any objection to all or part of the recommended decision, the Final Adjudication Branch (FAB) will issue a decision accepting the recommendation of the district office, either whole or in part." 20 C.F.R. § 30.316(a). On December 1, 2004, the FAB received your signed waiver of any and all objections to the recommended decision. After considering the evidence of record, your waiver of objection, and the NIOSH report, the FAB hereby makes the following:

FINDINGS OF FACT

1. You filed a claim for benefits under Part B of the EEOICPA on May 28, 2004.
2. Your husband was employed at the Paducah Gaseous Diffusion Plant for at least one day on December 17, 1954.
3. Medical evidence has been submitted establishing a diagnosis of chronic beryllium disease before January 1, 1993.

4. You were married to the employee from March 23, 1940, until his death on October 12, 1999.

Based on these facts, the undersigned makes the following:

CONCLUSIONS OF LAW

Section 7384s of the Act provides for the payment of benefits to a covered employee, or his survivor, with an "occupational illness," which is defined in § 7384l(15) of the EEOICPA as "a covered beryllium illness, cancer. . .or chronic silicosis, as the case may be." 42 U.S.C. §§ 7384l(15) and 7384s. 42 U.S.C. § 7384l.

Pursuant to § 7384l(13)(B) of the EEOICPA, to establish a diagnosis of CBD before January 1, 1993, the employee must have had "an occupational or environmental history, or epidemiologic evidence of beryllium exposure; and (iii) any three of the following criteria: (I) Characteristic chest radiographic (or computed tomography (CT)) abnormalities. (II) Restrictive or obstructive lung physiology testing or diffusing lung capacity defect. (III) Lung pathology consistent with chronic beryllium disease. (IV) Clinical course consistent with a chronic respiratory disorder. (V) Immunologic tests showing beryllium sensitivity (skin patch test or beryllium blood test preferred)." 42 U.S.C. § 7384l(13)(B).

The evidence of record establishes that the employee was a covered beryllium employee who had at least three of the five necessary medical criteria to establish pre-1993 CBD under the EEOICPA. Therefore, you have provided sufficient evidence to establish that your husband was diagnosed with pre-1993 CBD, pursuant to § 7384l(13)(B) of the EEOICPA.

The undersigned has reviewed the facts and the district office's November 30, 2004 recommended decision and finds that you are entitled to \$150,000 in compensation.

The decision on the claim that you filed under Part E of the EEOICPA is being deferred until issuance of the Interim Final Regulations.

Washington, DC

Tom Daugherty
Hearing Representative
Final Adjudication Branch

[1] The Paducah Gaseous Diffusion Plant was a DOE facility from 1952 to July 28, 1998 and July 29, 1998 to present (remediation) where radioactive and beryllium material were present, according to the Department of Energy Office of Worker Advocacy Facility List (<http://www.hss.energy.gov/HealthSafety/FWSP/Advocacy/faclist/findfacility.cfm>).

[2] Per Chapter 2-100.3h (January 2002) of the Federal (EEOICPA) Procedure Manual, "The OWCP may receive evidence from other sources such as other state and federal agencies" to support a claim under the EEOICPA.

[3] Per Chapter 2-700.4 (September 2004) of the Federal (EEOICPA) Procedure Manual, "To determine whether to use the Pre or Post 1993 CBD criteria, the medical evidence must demonstrate that the employee was either treated for, tested or diagnosed with a chronic respiratory disorder. If the earliest dated document is prior to January 1, 1993, the pre-1993 CBD criteria may be used. Once it is established that the employee had a chronic respiratory disorder prior to 1993, the CE is not limited to use of medical reports prior to 1993 to meet the three of five criteria."

Delories J. Allen's X-Ray Records, CT Scan, and Misc. Medical Reports For Chronic Obstructive Pulmonary Disease (COPD) and Bronchitis Reflecting Compliance With Pre-1993 CBD Criteria

Dolores J. Allen provides Claimant Attachment (CA) – 001 that consists of her medical reports, x-ray reports, and her clinical treatment for her lung abnormalities bronchitis and chronic obstructive pulmonary disease (COPD) prior to January 1, 1993. On August 12, 2009, Dr. Fredic Rosenberg stated in his “Summary”... Mrs. Allen worked at Paducah Gaseous Diffusion Plant (GPD) from July 10, 1953 to December 31, 1961; and from June 1, 1976 to October 1, 1996. Ms. Allen filed a claim under Part E on April 24, 2009 for chronic bronchitis.....chronic obstructive pulmonary disease (COPD)....”

The DOL Paducah Site exposure Matrices (SEM) identified three substances that Ms. Allen could have been exposed to that are capable of causing chronic bronchitis and COPD, **“including ammonia, asbestos and uranium, “BUT DOL FAILED TO INCLUDE BERYLLIUM AS A PGDP SEM TOXIC SUBSTANCE”, IN VIOLATION OF THE “ADMINISTRATIVE PROCEDURES ACT”, EEOICPA, THE EEOICPA REGULATIONS, POLICIES AND PROCEDURES.**

Evidence of Dolores J. Allen's Chronic Obstructive Pulmonary Disease and Bronchitis (Lung Abnormalities) Diagnosed Before January 1, 1993 includes the following:

On January 14, 1976, Dolores J. Allen was examined by Union Carbide physician who stated that.... **“X-rays of the chest – show PARAENCHYMAL AND HILAR CALCIFICATIONS....”**

On November 8, 1976, Dolores J. Allen was examined by Union Carbide physician who stated that **“x-rays of the chest – show PARAENCHYMAL AND HILAR CALCIFICATIONS....”**

On October 3, 1984, an x-ray showed...**“FIBROSIS IN THE RIGHT LUNG BASE.”**

On May 7, 1993, Dr. Bailey W. Culbertson stated on a “C-T Scan Report” = **“ENHANCED CT SCAN OF THE CHEST FOR NEW ILL-DEFINED INFILTRATE IN THE LEFT LOWER CHEST”**: Examination reveals a **“NECROTIC IRREGULAR PERIPHERAL INFILTRATE IN THE ANTERIOR SEGMENT OF THE LEFT LOWER LOBE MEASURING 4 1/2 X 2 1/2 CM. IT IS ADJACENT TO THE CHEST WALL....”**
.....“IMPRESSION” – ILL-DEFINED 4 X 3 CM. PARENCHYMAL MASS IN THE ANTERIOR SEGMENT OF THE LEFT LOWER LOBE ...”

On August 12, 2009, Dr. Fredic Rosenberg stated in his “Summary”... “Mrs. Allen worked at Paducah Gaseous Diffusion Plant (GPD) from July 10, 1953 to December 31, 1961; and from June 1, 1976 to October 1, 1996. **Ms. Allen filed a claim under Part E on April 24, 2009 for chronic bronchitis.....chronic obstructive pulmonary disease**

(COPD)....” The DOL Paducah Site exposure Matrices (SEM) identified three substances that Ms. Allen could have been exposed to that are capable of causing chronic bronchitis and COPD, “including ammonia, asbestos and uranium, **BUT DOL FAILED TO INCLUDE BERYLLIUM AS A PGDP SEM TOXIC SUBSTANCE.**


Request for Approval of Part B and Part E Compensation and Medical Benefits for Chronic Beryllium Disease (CBD)

Based on the above medical evidence, Dolores J. Allen has met her burden of proof for EEOICPA Part B Compensation in the amount of \$150,000 and EEOICPA Part E compensation based on the maximum whole body impairment of 100% in the amount of \$250,000, per the statutory requirements USC § 73841 (13) (B) and Chapter 2-700.4 (September 2004) of the Federal (EEOICPA) Procedure Manual established for all sick nuclear workers per the Act.

More importantly, Dolores J. Allen is entitled to medical benefits for her diagnosed illness of Chronic Beryllium Disease, that includes all consequential illnesses that are related to her CBD.

Please feel free to contact me at 270-559-1752 or 270-450-0850.

Sincerely,



Gary S. Vander Boegh

“Authorized Representative”

Vice President- Commonwealth Environmental Services, LLC.

Cc. Honorable Secretary of Labor Hilda Solis w/Attach (Priority Mail) & fax (202) 693-6111

U.S. Department of Labor
200 Constitution Avenue, NW
Room S-2018
Washington, DC 20210

**Claim for Benefits Under the Energy Employees
Occupational Illness Compensation Program Act**

U.S. Department of Labor
Employment Standards Administration
Office of Workers' Compensation Programs



Note: Provide all information requested below. Do not write in the shaded areas. OMB Number: 1215-0197
Expiration Date: 08/31/2010

Employee Information (Please Print Clearly)

1. Name (Last, First, Middle Initial) Allen Dolores J		2. Social Security Number 407-40-9972	
3. Date of Birth 01 / 25 / 1935 Month Day Year	4. Sex <input type="checkbox"/> Male <input checked="" type="checkbox"/> Female	5. Dependents <input checked="" type="checkbox"/> Spouse <input type="checkbox"/> Children <input type="checkbox"/> Other:	
6. Address (Street, Apt. #, P.O. Box) 375 Whippoorwill Lane (City, State, ZIP Code) Paducah KY 42001		7. Telephone Number(s) a. Home: (270) 554 - 4014 b. Other: () -	

8. Identify the Diagnosed Condition(s) Being Claimed as Work-Related (check box and list specific diagnosis)

	9. Date of Diagnosis		
	Month	Day	Year
<input type="checkbox"/> Cancer (List Specific Diagnosis Below)			
a.			
b.			
c.			
<input type="checkbox"/> Beryllium Sensitivity			
<input checked="" type="checkbox"/> Chronic Beryllium Disease (CBD)	01	14	1976
<input type="checkbox"/> Chronic Silicosis			
<input type="checkbox"/> Other Work-Related Condition(s) due to exposure to toxic substances or radiation (List Specific Diagnosis Below)			
a.			
b.			
c.			

Awards and Other Information

10. Did you work at a location designated as a Special Exposure Cohort (SEC)?	<input checked="" type="checkbox"/> YES <input type="checkbox"/> NO
11. Have you filed a lawsuit seeking either money or medical coverage for the above claimed condition(s)?	<input type="checkbox"/> YES <input checked="" type="checkbox"/> NO
12. Have you filed any workers' compensation claims in connection with the above claimed condition(s)?	<input type="checkbox"/> YES <input checked="" type="checkbox"/> NO
13. Have you or another person received a settlement or other award in connection with a lawsuit or workers' compensation claim for the above claimed condition(s)?	<input type="checkbox"/> YES <input checked="" type="checkbox"/> NO
14. Have you either pled guilty or been convicted of any charges connected with an application for or receipt of federal or state workers' compensation?	<input type="checkbox"/> YES <input checked="" type="checkbox"/> NO
15. Have you applied for an award under Section 5 of the Radiation Exposure Compensation Act (RECA)?	<input type="checkbox"/> YES <input checked="" type="checkbox"/> NO
If yes, provide RECA Claim #: <input type="text"/>	
16. Have you applied for an award under Section 4 of the Radiation Exposure Compensation Act (RECA)?	<input type="checkbox"/> YES <input checked="" type="checkbox"/> NO

Employee Declaration

Any person who knowingly makes any false statement, misrepresentation, concealment of fact, or any other act of fraud to obtain compensation as provided under EEOICPA or who knowingly accepts compensation to which that person is not entitled is subject to civil or administrative remedies as well as felony criminal prosecution and may, under appropriate criminal provisions, be punished by a fine or imprisonment or both. Any change to the information provided on this form once it is submitted must be reported immediately to the district office responsible for the administration of the claim. I hereby make a claim for benefits under EEOICPA and affirm that the information I have provided on this form is true. If applicable, I authorize the Department of Justice to release any requested information, including information related to my RECA claim, to the U.S. Department of Labor, Office of Workers' Compensation Programs (OWCP). Furthermore, I authorize any physician or hospital (or any other person, institution, corporation, or government agency, including the Social Security Administration) to furnish any desired information to the U.S. Department of Labor, Office of Workers' Compensation Programs.

 Employee Signature 09/10/2010 Date

Resource Center Date Stamp



UNION CARBIDE CORPORATION
NUCLEAR DIVISION

009591

X-RAY EXAMINATIONS BD: 1-25-35

Medical No. 2484 Name ALLEN, DOLORES JUNE (McCLURE) Reading

1-14-76
~~Per-Exp.~~
Rehire

X-rays of the chest - show a few parenchymal and hilar calcifications without evidence of active lung disease.

RHR:reb

11-08-76

X-rays of the chest - show a few parenchymal and hilar calcifications without evidence of active lung disease.

RHR:icz

✓9/14/78
Per.

Chest: The heart is normal in size and shape. The lungs are normally expanded and are free of active parenchymal disease. The mediastinal structures are not displaced and both hemidiaphragms are normal. There is no pleural change and the bony thorax is intact.

Impression: Normal Chest.

PB:ejw

✓3-31-80
Per.

Chest: Re-examination in comparison with the last old film shows no change.

Impression: Normal chest.

WHS:pm

✓9-23-81
Per

Chest: The heart is normal in size and shape. The lungs are normally expanded and aerated and are free of active parenchymal disease.

Impression: Normal chest.

PB:ejw

2-3-83

Left Ankle: and Left Foot: All views appear normal.

PB:ejw

OFFICIAL USE ONLY

aur

X-RAY REPORT

NAME: Allen, D. J.
 MEDICAL NO: 2484 (9591)
 DATE: 10/3/84

CHEST:

The chest appears normal. It is noted, however, that there is very slight fibrosis in the right lung base. This is old and does not appear significant. Also noted is the trachea projecting somewhat to the right of midline at the thoracic inlet. I believe this is related to the position of the head only as the head appears turned to the right side.

IMPRESSION:

Normal chest.

PB:ah

03-26-86

CHEST ERECT PA AND LATERAL ROUTINE: Examination is compared to a previous one of 10/03/84.

As compared to the previous exam, there has been no gross dramatic change in the appearance of the cardio-pulmonary thoracic structures. There is an area of fibrosis in the medial right basilar segment--unchanged.

No active or metastatic disease--negative chest

KHC/cch

Copy to pt. 8-8-88

OFFICIAL USE ONLY

CLAIMANT ATTACHMENT 001

CRAWFORD RADIOLOGY CLINIC, P.S.C.

KEITH HOWARD CRAWFORD, M.D.
FRANK B. CRAWFORD, JR., M.D.
GERSH BERG, M.D.
BROADWAY PROFESSIONAL BLDG.
2421 BROADWAY
PADUCAH, KENTUCKY 42001
TELEPHONE 442-8272-3

RADIOLOGY
X-RAY DIAGNOSIS
BREAST EVALUATION
ULTRASONOGRAPHY
C-T SCANNING

OFFICE HOURS
Mon. thru Fri.
7:30 a.m.-4:30 p.m.

DATE 05-07-93

Patient ALLEN, DOLORES DOB: 01-25-35 Referring Doctor B. Bailey, W. Culbertson

Examination CT of chest Age 58 X-Ray No. 238793

C-T SCAN REPORT

History or Clinical Problem:

REPORT ON DIAGNOSTIC CONSULTATION

ENHANCED CT SCAN OF THE CHEST FOR NEW ILL-DEFINED INFILTRATE IN THE LEFT LOWER CHEST: Examination reveals a necrotic irregular peripheral infiltrate in the anterior segment of the left lower lobe measuring 4 1/2 x 2 1/2 cm. It is adjacent to the chest wall.

Fortunately, we can perceive no obvious lymphadenopathy in the mediastinum. There is no fluid in the left chest cavity.

The liver and spleen are unremarkable.

IMPRESSION: ILL-DEFINED 4 x 3 CM. PARENCHYMAL MASS IN THE ANTERIOR SEGMENT OF THE LEFT LOWER LOBE -- CONSISTENT WITH CARCINOMA VERSUS NECROTIC PULMONARY INFARCTION VERSUS ORGANIZING PNEUMONIA OR ABSCESS.

COMMENT: Since Dr. Bailey was on vacation, he had discussed with her consulting a pulmonologist if her hemoptysis did not improve -- she wished me to go ahead and schedule her an appointment -- and we did so. She understands the situation.

KHC/cl

Karl...
RECEIVED

Paducah Resource Center M.D.
RADIOLOGIST

CLAIMANT ATTACHMENT APR 24 2009 Transmitted to DOL-DO

PAGE NO. 303 APR 29 2009

Medical Confidential

External DMC Referral

From: Fredric Rosenberg, JD, DO, MPH
3270 Cochise Drive
Atlanta, Georgia 30339
(770) 434-1753
(770) 434-7512 fax
fr1753@aol.com
Provider Number 611-00-1900

To: Cassandra Watts
Claims Examiner
USDOL/ESA/OWCP/EEOICP
400 West Bay Street
Room 722
Jacksonville, Florida 32202-4410
(904) 357-4795
(904) 357-4704 fax
Watts.Cassandra@dol.gov

Date: August 12, 2009 (revised August 6, consultation)

Re: Dolores Allen

File number: 407-40-9972

Date of Birth: January 25, 1935

Summary: Dolores Allen was born on January 25, 1935. She worked as a Laboratory Aid, Laboratory Analyst, and Senior Laboratory Technician at Paducah Gaseous Diffusion Plant (GDP) from July 10, 1953 to December 31, 1961; and from June 1, 1976 to October 1, 1996. Ms. Allen filed a claim under Part B on March 30, 2005 that was denied on November 16, 2005. She also filed a claim under Part E on April 24, 2009 for Chronic Bronchitis, Rheumatoid Arthritis, Hypothyroidism, Sinusitis, Chronic Obstructive Pulmonary Disease (COPD), Osteoporosis and Parenchymal Mass (Lower Lobe). Site Exposure Matrices (SEM) identified three substances that Ms. Allen could have been exposed to that are capable of causing Chronic Bronchitis and COPD, including ammonia, asbestos, and uranium. SEM did not list other substances that Ms. Allen had potential exposure at GDP that can cause Hypothyroidism, Sinusitis, and Osteoporosis. Parenchymal Mass is not a specific diagnosis that could be listed in SEM.

Medical Confidential

It is not at least as likely as not, that exposure to toxins at GDP was a significant factor in causing, contributing to, or aggravating the claimed conditions.

Discussion: Ammonia is a severe eye, respiratory, and skin irritant. Generally chronic effects of ammonia inhalation are only seen after an acute inhalation episode. A case report described a man who was chronically exposed to ammonia who did not have any acute episodes, but developed pulmonary fibrosis. In another study, chronic exposure to average ammonia levels above 25 parts per million (ppm) was associated with an increase in respiratory symptoms and bronchial asthma [Jyrki Liesivuori, The Nordic Expert Group for Criteria Documentation of Health Risks from Chemicals, Ammonia, Archives of Environmental Health 2003, Volume 58, Pages 592-596]. As noted below, Ms Allen does not have current symptoms of chronic bronchitis or COPD. The records from workplace examinations do not discuss any acute inhalation of ammonia or pulmonary abnormalities while she worked at GDP. The workplace medical exams do not identify, by medical history or physical examination, any pulmonary conditions while Ms. Allen worked at GDP. It is not likely that ammonia caused either chronic bronchitis or COPD for Ms. Allen.

Asbestos can cause pleural effusion, pleural plaques, pleural thickening, diaphragmatic plaques, asbestosis, mesothelioma, and lung cancer [CS Glazer, LS Newman, Occupational Interstitial Lung Disease, Clinics in Chest Medicine 2004, Volume 25, Page 470]. Asbestos has been associated with COPD [American Thoracic Society, American Journal of Respiratory and Critical Care Medicine, Diagnosis and Initial Management of Nonmalignant Diseases Related to Asbestos, Volume 170, Pages 708 -710]. It is controversial whether asbestos causes lung obstruction [Rom, Environmental and Occupational Medicine, Fourth Edition, page 302], but is probably more likely to occur when the B-reader chest x-ray interpretation is consistent with high-level asbestos exposure. The B-reader report of July 16, 2008 did not note any parenchymal or pleural abnormalities consistent with asbestosis or any pneumoconiosis. It is unlikely that asbestos caused chronic bronchitis or COPD for Ms. Allen.

Although uranium can act as a pulmonary irritant, kidney toxicity is the most likely non-cancerous result of exposure to this heavy metal. [Gloria Hathaway and Nick Proctor, Proctor & Hughes' Chemical Hazards of the Workplace, Fifth Edition, Page 722-724]. Pulmonary disease from uranium exposure is not likely without kidney disease also present. The medical records do not indicate that Ms. Allen has kidney toxicity. On July 16, 2008 the lab reported normal values for urea nitrogen and creatinine of 13 mg/dl and 0.79 mg/dl respectively and the urinalysis did not demonstrate proteinuria. These lab values are consistent with normal kidney function. Uranium did not cause chronic bronchitis or COPD for Ms. Allen.

Chronic bronchitis and COPD are both obstructive lung disorders. Chronic bronchitis includes a history of productive cough for at least three months in two consecutive years. This definition helps to distinguish other pulmonary conditions, such as acute bronchitis [JM Heath, R Mongia, Chronic Bronchitis: Primary Care Management, American Family Physician, 1998, Volume 57(10), Page 2365-2372]. Acute bronchitis usually resolves

CLAIMANT ATTACHMENT 002PAGE NO. 2 of 5

Medical Confidential

after treatment without lasting effects. Diagnosis of chronic bronchitis also requires a demonstration of obstruction on pulmonary function testing. The medical records do not establish a pattern of chronic sputum production consistent with chronic bronchitis, nor do they show obstructive disease with pulmonary function testing.

COPD is diagnosed when a patient has increasing sputum production, progressive dyspnea or shortness of breath, and a pulmonary function test that demonstrates a forced expiratory volume at one second (FEV1)/ forced vital capacity (FVC) ratio of less than 70% [MB Stephens and KS Yew, Diagnosis of chronic obstructive pulmonary disease, American Family Physician, 2008, Volume 78(1), Pages 87-92]. Asthma can be distinguished from COPD by showing a significant improvement in pulmonary function after administration of an inhaled bronchodilator. Obstruction can also be shown by a decrease in FEV1, and a decrease in forced mid- expiratory flow (FEF25-75%). Although some of the x-ray reports suggested COPD due to hyperinflation, the pulmonary function tests showed normal values. The pulmonary function test is more specific for diagnosis of obstructive lung disorders than chest x-rays.

Pulmonary function tests performed on July 16, 2008 indicated that FVC was 91%, FEV1 98%, FEV1/FVC 108%, and FEF 25-75% 129%; all normal values. The medical records, provided by Jesse Wallace, MD, an internal medicine specialist, Internal Medicine Group, Paducah, Kentucky showed no pulmonary symptoms for the medical history and normal lung findings during the physical examinations on April 10, 2007; July 12, 2007; September 11, 2007; January 10, 2008, September 16, 2008; and March 17, 2009. The progress notes also noted normal sinus and nasal histories and examinations for those days, and there were no discussions of pulmonary inhaled medication to treat either COPD or chronic bronchitis.

Because Ms. Allen has normal pulmonary function and no indication of obstructive disease it is not likely that she has either COPD or chronic bronchitis. It is unlikely that ammonia, asbestos, or uranium caused COPD or chronic bronchitis for Ms. Allen.

The CT scan of the head performed on March 26, 2009 noted that there was evidence of chronic sinusitis. In 2004 Dr. Wallace described sinus and nasal symptoms that fluctuated. On August 24, 2004 Dr. Wallace said that Ms. Allen also had eye irritation, that suggested an allergic response. He therefore added Zyrtec, an antihistamine, to her drug regimen. Allergic rhinitis and sinusitis often exhibit eye irritation. The likely etiology of Ms. Allen's rhinitis and sinusitis, based on medical history and examination is allergic. It is unlikely that Ms. Allen's sinusitis was caused by ammonia, asbestos, or uranium.

The cause of rheumatoid arthritis is not known, but it is believed to be an interaction between genetic predisposition and environmental factors [JA Rindfleisch, D Muller, Diagnosis and management of rheumatoid arthritis, American Family Physician, 2005, Volume 72(6), pages 1037-1047]. Rheumatoid arthritis is an autoimmune disorder that is capable of causing severe crippling disease. The record clearly documents that Ms. Allen

CLAIMANT ATTACHMENT 002
PAGE NO. 3 of 5

Medical Confidential

has severe rheumatoid arthritis. Because there is no known cause for rheumatoid arthritis, this condition cannot be attributed to toxic exposures at a DOE facility.

Hypothyroidism has many causes, including Hashimoto's thyroiditis, treatment of hyperthyroidism, surgical removal of the thyroid gland, iodine deficiency, drug therapy, and sarcoidosis. The most common presentation of hypothyroidism is an unknown etiology believed to be the result of an undetected thyroiditis [WJ Hueston, Treatment of hypothyroidism, American Family Physician, 2001, Volume 64(10), Pages 1717-24]. Ms. Allen's hypothyroidism is not likely due to exposure to toxic substances at a DOE facility.

Osteoporosis has several risk factors, including female gender, menopause, corticosteroid treatment, hypothyroidism and rheumatoid arthritis [National Osteoporosis Foundation, NOF. org]. The medical records indicated that she had all of these five risk factors, which are the likely cause of her osteoporosis. It is unlikely that exposure to toxic substances at a DOE facility caused Ms. Allen's osteoporosis.

The report of a CT scan of the chest performed on Ms. Allen on May 7, 1993 noted that there was an ill-defined 4 cm by 3 cm parenchymal mass in the anterior segment of the left lower lobe. Ms. Allen was referred to Dr. Clarke, a pulmonary specialist, to determine the diagnosis of the abnormality noted on the CT scan. She was diagnosed with a pulmonary abscess, which resolved with treatment. Subsequent x-rays do not show that Ms. Allen has a mass in her left lower lung field. The abscess was caused by an infection, and not caused by exposure to toxic substances at a DOE facility. The abscess has resolved, and she no longer has a parenchymal mass.

Responses to questions: 1. It is not at least as likely as not, that exposure to toxic substances at a DOE facility, was a significant factor in causing, aggravating, or contributing to Chronic Bronchitis, Rheumatoid Arthritis, Hypothyroidism, Sinusitis, Chronic Obstructive Pulmonary Disease (COPD), Osteoporosis, and a Parenchymal Mass (Lower Lobe) for Dolores Allen.

The medical records do not demonstrate that Ms. Allen has COPD or chronic bronchitis. Her pulmonary function tests are normal. Her sinus condition is due to allergy (allergic rhinitis/sinusitis) and not exposure to toxic substances at a DOE facility. The cause of her rheumatoid arthritis and hypothyroidism are not known and are not likely caused by toxic substances. The cause of rheumatoid arthritis, an autoimmune disorder, is not known. The cause of hypothyroidism is frequently not known. Osteoporosis was caused by Ms. Allen's medical conditions, or risk factors, that are not related to exposure to toxic substances. The parenchymal mass was a lung abscess that resolved. The abscess was due to an infection and not exposure to toxic substances at a DOE facility.

I certify that I am an expert in the required areas of medical expertise for the issues raised in this case and this is my objective medical opinion provided in accordance with the

CLAIMANT ATTACHMENT 002


PAGE NO. 4 of 5

Medical Confidential

DDEOIC program procedures and guidelines. I also certify that I neither have now, nor in the past, any relationship with the claimant, his/her physicians, their attorneys, representatives or any employee, employer, manufacturer or entity that may be connected with this case that would influence my opinion in any way. I also certify that my opinion was not influenced by any financial consideration that may benefit me, my family or my heirs.

Thank you, for allowing me to participate in this evaluation. Please contact me if you have any additional questions.

Sincerely,



Fredric Rosenberg, JD, DO, MPH
District Medical Consultant
Georgia License Number 022044


CLAIMANT ATTACHMENT 002

PAGE NO. 5 of 5

*** FAX MULTI TX REPORT ***

JOB NO.	3648
DEPT. ID	151
PGS.	16
TX IMCOMPLETE	-----
TRANSACTION OK	919043574704
	912026936111
ERROR	-----

COMMONWEALTH ENVIRONMENTAL SERVICES, LLC
A Native American Woman Owned Company



Fax Cover Sheet

To: Hilda Solis & Mr. Bibeault

From: Gary S. Vander Boegh

Fax: (904) 357-4704
(202) 693-6111

Date: 9-10-10

Phone:

Pages: ___ Pages including the Cover Sheet

Re: Dolores J. Allen

CC: Attention Jim Bibeault

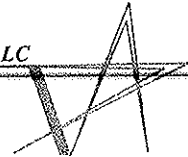
Urgent For Review Please Comment Please Reply Please Recycle

Comments:

*** TX REPORT ***

JOB NO. 3648
DEPT. ID 151
ST. TIME 09/10 17:05
PGS. 16
SEND DOCUMENT NAME
TX IMCOMPLETE -----
TRANSACTION OK 919043574704
912026936111
ERROR -----

COMMONWEALTH ENVIRONMENTAL SERVICES, LLC
A Native American Woman Owned Company



Fax Cover Sheet

To: Hilda Solis & Mr. Bibeault

From: Gary S. Vander Boegh

Fax: (904) 357-4704
(202) 693-6111

Date: 9-10-10

Phone:

Pages: ___ Pages including the Cover Sheet

Re: Dolores J. Allen

CC: Attention Jim Bibeault

Urgent For Review Please Comment Please Reply Please Recycle

Comments:

