

Neonatal form of dystrophia myotonica

Five cases in preterm babies and a review of earlier reports

R. G. PEARSE AND C. J. HÖWELER

Departments of Paediatrics and Neurology, Sophia Children's Hospital, and Academic Hospital, Erasmus University, Rotterdam

SUMMARY Five preterm babies with the neonatal form of dystrophia myotonica are reported. In addition to the generally accepted signs and symptoms of the disease, two other features were present in these patients; oedema was notable in all 5 babies and 4 had unexplained haematomas. It is suggested that premature birth may be a result of severe involvement and that prematurity further aggravates the symptoms.

The neonatal form of dystrophia myotonica is now recognised as a clinical entity which is quite different from the adult form of the disease (Vanier, 1960). The clinical picture is characteristic and consists of extreme hypotonia and generalised muscle atrophy, combined with polyhydramnios, insufficient respiratory activity after birth, joint deformities, and facial diplegia with a 'tent-shaped' mouth. The adult form of the disease, however, comprises myotonia and localised muscle atrophy with cataracts, frontal baldness, and testicular atrophy.

In a 7-month period, 5 preterm babies in whom the diagnosis of dystrophia myotonica could be made were admitted to our neonatal intensive care unit. We describe these babies, report two hitherto unstressed features of this disease, and review previous reports on the neonatal form of dystrophia myotonica.

Case reports

Case 1. A baby girl was delivered by caesarean section at another hospital at 30 weeks' gestation because of abruptio placentae. The pregnancy had been complicated by polyhydramnios. After delivery the baby made no spontaneous attempt to breathe and was ventilated by mask until the arrival of our neonatal transport team. She was intubated and given intermittent positive pressure ventilation (IPPV).

On admission she weighed 1840 g and was hypotonic (Fig. 1a) with a 'tent-ed' upper lip (Fig. 1b),

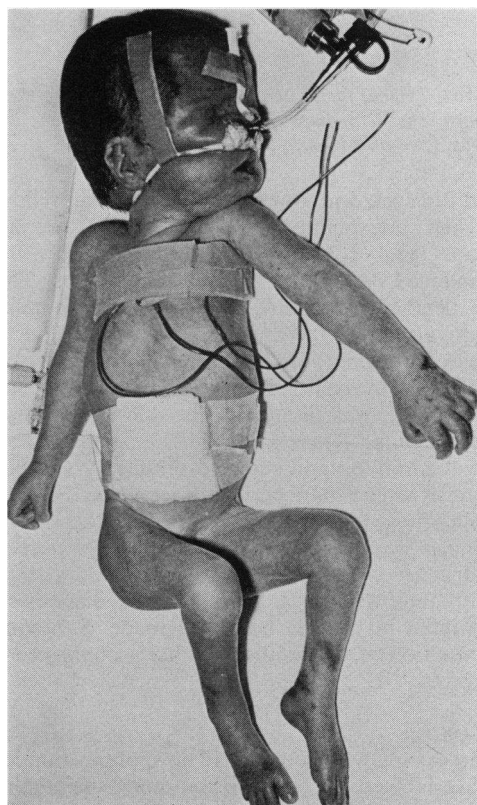


Fig. 1a Characteristic posture of the premature infant with dystrophia myotonica. Hypotonia of the shoulder girdle can be seen with muscle atrophy in the legs and flexion contractures of the hips and talipes equinovarus.

Sophia Children's Hospital and Neonatal Unit, Rotterdam, The Netherlands

R. G. PEARSE, consultant paediatrician
C. J. HÖWELER, neurologist

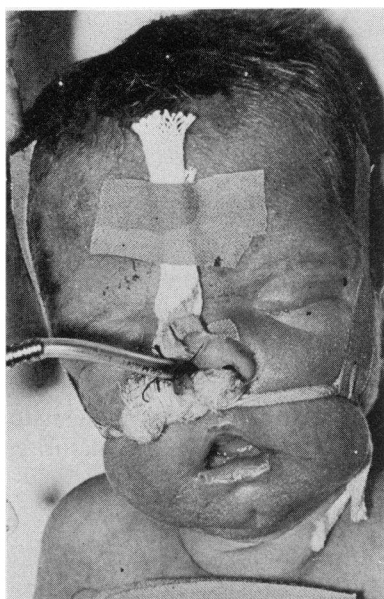

Fig. 1b *Typical facies of dystrophia myotonica in the newborn. The 'tent shaped' mouth and oedema are obvious. (See also Figs 3, 5, 7, and 9.)*

facial diplegia, and absent sucking and gag reflexes. She had unexplained haematomas of the labia minora (Fig. 1c), upper thighs, and arms, and pronounced oedema of the head and limbs. There were flexion contractures of the hips with talipes equinovarus, and the muscles of the arms and legs appeared atrophic (Fig. 1a). She lost 450 g (24% of birthweight) in the first 5 days in spite of intravenous feeding. This was thought to be due to the loss of oedema fluid. There was little change in her clinical condition and she died on day 19 without a diagnosis other than perinatal asphyxia. Necropsy examination gave no cause for her death. The diagnosis was made when the similarity was recognised between this baby and a baby admitted one month later (Case 2) in whom the diagnosis of dystrophia myotonica had been made. Subsequent examination of the mother of Case 1 confirmed the diagnosis.

The mother

A 33-year-old woman who had no spontaneous complaints. However on direct questioning she admitted to having had 'stiff hands' during this and previous pregnancies. On examination she had the classic findings of moderately severe dystrophia myotonica with a myopathic facies (Fig. 2), weakness of distal limb muscles, and myotonia of grip. She has two healthy children now aged 3 and 6 years. They have

both been examined and have no symptoms or signs of dystrophia myotonica, but EMG and slit-lamp examination could not be performed. Her third pregnancy ended at 28 weeks with the delivery of a

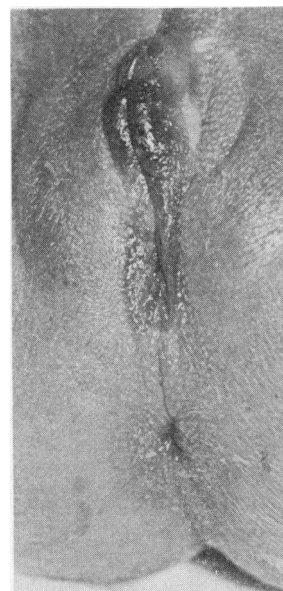


Fig. 1c *Haematoma of the labia minora.*

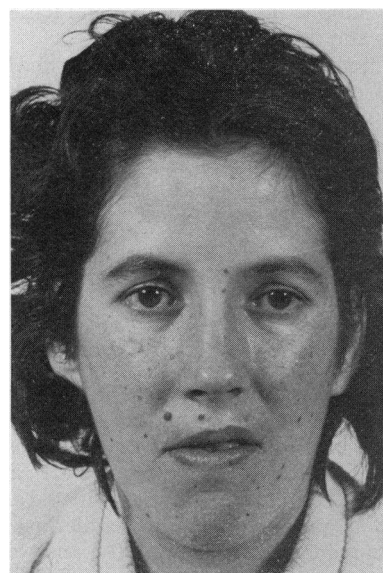

Fig. 2 *Mother of Case 1. Typical facies of dystrophia myotonica. Atrophy of the temporalis and masseter muscles can be seen, also ptosis and the typical smile of facial muscle weakness. (See also Figs 4, 6, 8, and 10.)*

1640 g baby who died soon after birth from respiratory insufficiency, supposedly secondary to prematurity. Four of the mother's five sisters have been shown to have dystrophia myotonica.

Case 2. A baby girl was born at home by spontaneous vaginal delivery at 36 weeks' gestation after a pregnancy complicated by polyhydramnios. She failed to breathe adequately after birth and was transferred to our hospital. On admission she weighed 2820 g and was cyanotic, hypotonic, hypothermic (34.4°C), and markedly oedematous. She had a 'tent-shaped' mouth (Fig. 3), facial diplegia, atrophy of limb muscles, and haematomas of the dorsal and palmar aspects of both hands for which no explanation could be found. Coagulation studies were normal. A differential diagnosis of cerebral haemorrhage or muscle disease was made. Lumbar puncture produced freely blood-stained CSF and CAT scan showed subarachnoid, interstitial, and intraventricular haemorrhage. A detailed family history taken at this time led to the diagnosis of dystrophia myotonica and subsequent examination of the mother confirmed this. During the first few days after birth the baby had episodes of apnoea and bradycardia of varying duration from which she spontaneously recovered. Thereafter the respiration improved and she began to move spontaneously. She still had difficulty in drinking and swallowing on discharge from hospital at age 7½ weeks when she weighed 3240 g. Her maximum weight loss in the first week was 480 g (17% of birthweight). She learned to sit unsupported and to roll at age 8

months. She is now 11 months and can stand with support, although she is unable to pull herself up to a sitting or standing position.

The mother

A 23-year-old woman who was unaware that she had dystrophia myotonica, although on questioning she had had myotonic symptoms in the hands since age 13. On examination she had mild but typical features of dystrophia myotonica (Fig. 4), including the characteristic cataracts and the EMG. Her father and brother were also found to have dystrophia myotonica. This was her first pregnancy.

Case 3. A baby girl was delivered by the breech at 33 weeks' gestation after a pregnancy complicated by polyhydramnios. She did not breathe spontaneously and during resuscitation attempts at introducing a nasogastric tube were unsuccessful, so that she was initially diagnosed as having oesophageal atresia. She was intubated and given IPPV, and then transferred to our hospital.

On admission she weighed 1350 g and was extremely hypotonic and oedematous. She made no spontaneous movements and was areflexic. She had generalised muscle atrophy with bilateral talipes equinovarus and flexion contractures of the hands and hips. There was a facial diplegia, a 'tent-shaped' mouth (Fig. 5), and haematomas over the limbs and upper thoracic and neck regions. Without IPPV she rapidly became cyanotic even in 100% O₂. There was no evidence of oesophageal atresia and the diagnosis of the neonatal form of dystrophia myotonica was made on the clinical findings, subsequently confirmed when we examined the mother. After 3 days

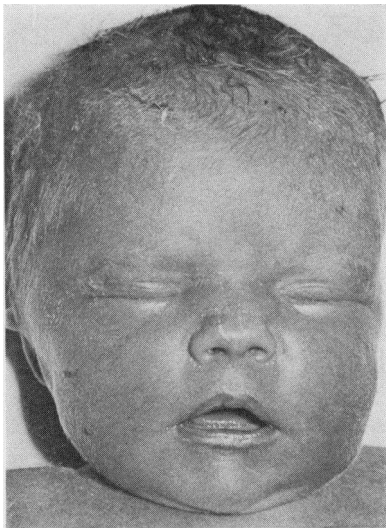

Fig. 3 Case 2, showing same features as in Fig. 1b.

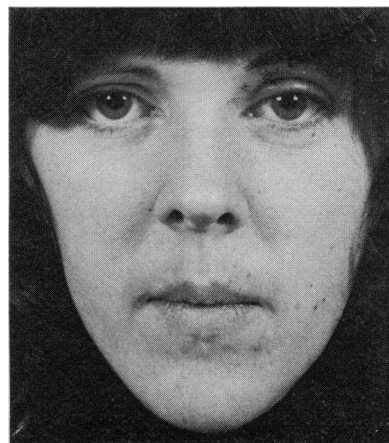

Fig. 4 Mother of Case 2, showing same features as in Fig. 2.

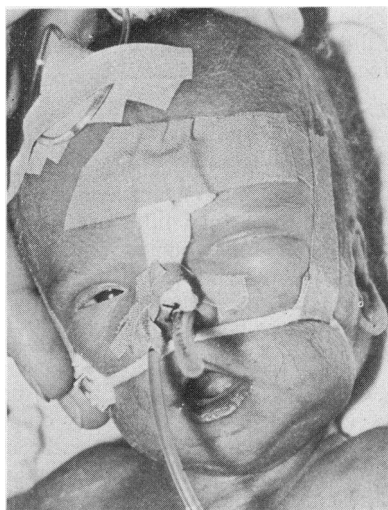

Fig. 5 Case 3, showing same features as in Fig. 1b.

on IPPV the baby died. At necropsy examination a subcapsular haematoma of the liver was found, plus the unexpected finding of agenesis of the corpus callosum. A coagulation screen done at age 24 hours was normal. Her maximum weight loss was 200 g (15% of birthweight).

The mother

A 21-year-old woman who had noticed myotonic symptoms since age 6 but, as she was familiar with them from her mother, uncle, and aunt, she had never reported them. She is mentally retarded and has an indistinct nasal speech. On examination she had typical myopathic facies (Fig. 6) and the findings of moderately severe dystrophia myotonica were confirmed by the EMG. This was her first pregnancy.

Case 4. A baby girl was born at another hospital at 34 weeks' gestation after a pregnancy complicated by polyhydramnios (9 litres) and premature contractions which had been treated with ritodrinechloride for one week. She was ventilated with a mask for 15 minutes but then was able to maintain a reasonable colour in 100% O₂. On admission to our hospital she weighed 2000 g and was hypotonic and oedematous. She had the typical facies of the neonatal form of dystrophia myotonica (Fig. 7), the muscles of her arms and legs were atrophic, and her feet were held in plantar flexion. There were haematomas of both legs and feet. Her respiration was inadequate and she was intubated and ventilated for 19 days. She developed congestive cardiac failure secondary to a patent ductus arteriosus which closed spontaneously.

She had had difficulty with drinking but was discharged at 10 weeks weighing 3060 g. Her maximum weight loss in the first week was 445 g (22% of birthweight). She is now 7 months old but does not roll or sit. Her head control is poor but is improving.

The mother

A 26-year-old woman who was unaware of her muscle disease, although on direct questioning she




Fig. 6 Mother of Case 3, showing same features as in Fig. 2.

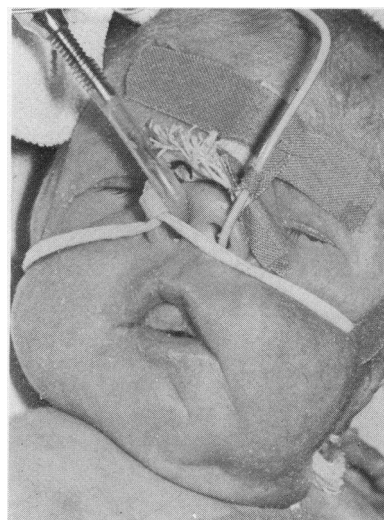


Fig. 7 Case 4, showing same features as in Fig. 1b.

had had myotonia of grip since age 18. On examination she had an obvious but mild degree of dystrophia myotonica (Fig. 8) and this was confirmed by the EMG. Her first pregnancy was complicated by polyhydramnios and ended at 33 weeks with the delivery of a baby who was hypotonic and did not breathe, attempts at resuscitation being unsuccessful. The mother's father has subsequently been shown to have a cataract typical of dystrophia myotonica although he has no muscle symptoms.

Case 5. A baby girl was delivered at 30 weeks' gestation at another hospital after a pregnancy complicated by polyhydramnios and a pyrexia of unknown origin just before delivery. The Apgar score was 3 at five minutes. She was intubated and transferred to our hospital on IPPV. On examination she was hypotonic and oedematous with the typical 'tent-shaped' mouth and facial diplegia (Fig. 9). Sucking and swallowing reflexes were absent and no tendon reflexes could be elicited. There were neither haematomas nor joint deformities but muscle atrophy was obvious. She was not weighed on admission but her weight was estimated to be about 2000 g. Her condition improved slowly but she required IPPV for 61 days. The clinical course was complicated by a patent ductus arteriosus which was closed surgically on day 44. She is now 6 months old and is still in hospital with feeding difficulties and recurrent pneumonia. She is hypotonic and is still being partially tube fed. She makes little or no contact.

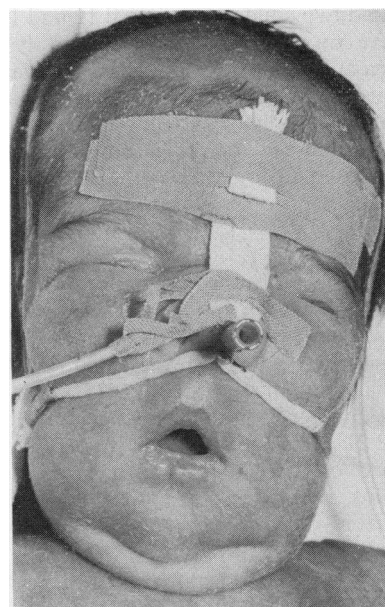


Fig. 9 Case 5, showing same features as in Fig. 1b.

The mother

A 37-year-old woman who was examined for dystrophia myotonica 4 months before the delivery because she is the sister of the mother of Case 1. She had had myotonic symptoms in the hands during this and the previous pregnancy although she had never complained of them. On examination she had obvious dystrophia myotonica of mild severity (Fig. 10) with cataracts and the typical EMG.

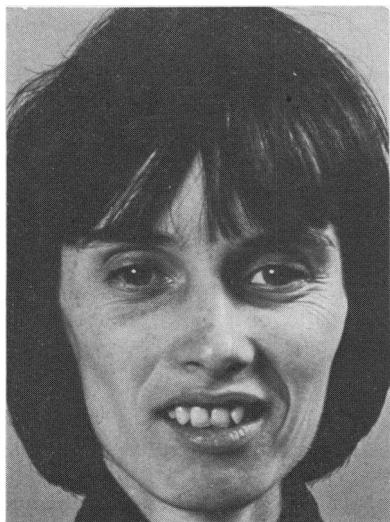


Fig. 8 Mother of Case 4, showing same features as in Fig. 2.



Fig. 10 Mother of Case 5, showing same features as in Fig. 2.

She has had two children now aged 11 and 13 years. They have no signs or symptoms of dystrophia myotonica and EMG and slit-lamp examination are normal in both. Her third pregnancy had been complicated by polyhydramnios and ended at 28 weeks with the delivery of a boy who failed to breathe, and died soon after birth.

Discussion

Dystrophia myotonica is a diagnosis which is easily missed in the newborn and is therefore probably not as rare as it would appear. This is supported by the high immediate postnatal mortality in families with dystrophia myotonica (Harper, 1975). The mother of Case 1 and her four affected sisters have between them had 21 babies of whom 8 have died soon after birth. In 5 of these there was documented polyhydramnios, suggesting that these babies died from dystrophia myotonica although the diagnosis was never made.

The individual symptoms of the disease as expressed in the newborn are nonspecific. However their occurrence in a particular combination makes recognition relatively easy. Some of these symptoms can be misleading. Severely affected babies often fail to establish adequate spontaneous respiration after birth. They are therefore diagnosed as having perinatal asphyxia, which may be considered adequate cause for the severe hypotonia seen. This receives apparent support when it is found that the baby also has difficulty with sucking and swallowing. However all these symptoms are an integral part of the neonatal form of dystrophia myotonica.

Harper (1975) described the characteristic features of the disease in newborn babies in his large retrospective study of 70 patients from 54 sibships. These are shown in the Table, together with the features described in 17 patients by other authors and in our series. There are obvious differences in the symptoms reported by Harper in this retrospective study and those reported in the series where the diagnosis was made in the neonatal period. All except one of the babies in Harper's series survived the neonatal period and only about half of them had respiratory difficulties. All the babies who were diagnosed in the neonatal period have had respiratory problems and half of them (11/22) have died.

The Table shows that the most commonly reported symptoms in the group diagnosed in the newborn period are respiratory insufficiency, hypotonia, joint deformities, and facial diplegia. Most of these babies have also had areflexia with muscle weakness and atrophy, and difficulty with sucking and swallowing. The inability to suck and swallow is probably the cause of the polyhydramnios (Dunn and Dierker,

Table *Reported frequency of various symptoms and signs (where these are given) compared with the incidence in this series*

Symptoms and signs	70 cases diagnosed retrospectively (Harper, 1975)	Reports* of 17 cases diagnosed in neonatal period	This study (5 cases)	Total cases diagnosed in neonatal period (22)
Respiratory problems	33/70	17/17	5/5	22/22
IPPV necessary	—	10/17	4/5	14/22
Hypotonia	47/70	17/17	5/5	22/22
Joint deformities	33/70	17/17	3/5	20/22
Facial diplegia	61/70	13/14	5/5	18/19
Areflexia	—	8/10	5/5	13/15
Muscle atrophy	—	4/4	5/5	9/9
Feeding problems	—	13/13	5/5	18/18
Oedema	—	2/2	5/5	7/7
Haematomas	—	—	4/5	4/5
Hydramnios	25/70	8/8	5/5	13/13
Mean birthweight (g)	3200	2900	1800	—
Mean gestational age (weeks)	39.5	39.5	32.6	—
Mortality	1/70	9/17	2/5	11/22
Transmission via mother	66/67	17/17	5/5	22/22
Delayed motor development	60/70	5/5	3/3	8/8

*L'Hirondel *et al.*, 1970; Bell and Smith, 1972; Messer *et al.*, 1973; Aicardi *et al.*, 1974; Bossen *et al.*, 1974; Simpson, 1975; Swift *et al.*, 1975; Sarnat *et al.*, 1976; van der Steeg *et al.*, 1977.

1973) which has been found in all cases in which the quantity of amniotic fluid has been reported.

We found that oedema was characteristic in our patients (Figs 1b, 3, 5, 9). The average weight loss in the four babies in whom this was accurately known was 19.5% of birthweight, whereas in our unit it is less than 10% of birthweight for babies of a similar gestational age who receive similar treatment regimens. This weight loss was thought to be largely due to the loss of oedema fluid. Clinically the oedema was most noticeable on the limbs and head, while the trunk appeared relatively spared. The muscle atrophy became more evident as the oedema disappeared. Oedema was also noted at birth in the patients reported by L'Hirondel *et al.* (1970) and Messer *et al.* (1973). An explanation for this oedema could be that secondary to reduced fetal movements there is reduction in lymphatic return from the periphery. The disappearance of the oedema in the first few days after birth may be related to the passive movements inherent in the intensive care of sick newborn babies.

A second notable feature in our cases was the existence of haematomas. In 4 of the 5 babies these were located in the skin, and one also had an intracerebral haemorrhage, and another baby a large subcapsular haematoma of the liver. Coagulation studies performed in 2 of the babies were normal. It can perhaps be postulated that these babies are unable to protect themselves against the trauma of delivery due

to muscular weakness and hypotonia. However Stern *et al.* (1978) showed that abnormal capillary leakage occurs in the iris of adults with dystrophia myotonica during fluorescein angiography. Microvascular abnormality may thus be an important factor in the formation of haematomas in these babies but has yet to be studied.

The diagnosis of the neonatal form of dystrophia myotonica is essentially clinical. There are no laboratory tests which are diagnostic in the newborn period. Both muscle biopsy and EMG give only supportive evidence and necropsy examination does not provide the diagnosis. If the diagnosis is suspected, it can be confirmed by examining the mother. Although the disease is transmitted as an autosomal dominant, the neonatal form always appears to be transmitted via the mother (Harper and Dyken, 1972). An initially negative family history does not exclude the diagnosis because the mother may be so mildly affected that she may be unaware that she has the disease. The signs which should be particularly sought are the characteristic facies (Figs 2, 4, 6, 8, 10) with facial weakness, hollow temples, myotonia of grip, and percussion myotonia of the thenar eminence. Inability to bury the lower eyelashes when closing the eyes tightly is a useful early sign of the disease in adults. Slit-lamp examination and EMG may be performed to confirm the diagnosis in the mother. Only one of the mothers in our series was known to have dystrophia myotonica at the time of delivery.

The differential diagnosis of the congenital form of dystrophia myotonica includes all the causes of the 'floppy infant' (Dubowitz, 1969). Thus cerebral depression from anoxia, trauma or drugs, spinal cord injury, neonatal myasthenia gravis, Werdnig-Hoffmann's disease, and other congenital myopathies should be considered.

Unlike the reported cases, all the babies in our series were preterm. Sarnat and Silbert (1976) suggested that the symptoms in the neonatal period are due to relative immaturity of muscle tissue. Thus more severe symptoms could be expected in the preterm baby. However, there is probably a spectrum of severity in the intrauterine involvement of babies with dystrophia myotonica, ranging from the fetus who is aborted early in the pregnancy, through the baby who is born preterm and dies soon after birth, to the term and mildly affected baby who survives. Thus the baby born preterm may be both more severely affected and have had less time in which maturation of muscle tissue could take place. As would be expected in severely affected babies, polyhydramnios was present in all of our cases, and was probably one of the factors responsible for the premature delivery. It may be possible to delay

delivery with uterine relaxants and by the repeated removal of excess amniotic fluid. This may moderate some of the life-threatening symptoms of the neonatal period by allowing the muscles more time to mature.

Harper and Dyken (1972) suggested that the neonatal form of dystrophia myotonica may be caused by an abnormal factor in the mother's serum which crosses the placenta but only affects babies carrying the abnormal gene. If this is so, then it is clear that it operates from early in pregnancy as our most premature affected infant was of 30 weeks' gestation and she already had joint contractures suggesting that the factor, if present, had been operative for some time.

Difficult ethical problems arise once the diagnosis has been made. If babies with dystrophia myotonica survive the first few weeks then there is a gradual improvement, at first in respiration, followed by improvement in swallowing, and eventually in the hypotonia. Although their development is slower than normal, most of them learn to walk and speak (Harper, 1975). However the long-term prognosis is poor and there is little hope of an independent life due to the combination of mental retardation and muscle weakness. Dyken and Harper (1973) found an average IQ of 56 in 14 patients who had had respiratory symptoms in the neonatal period.

Because the baby fails to breathe adequately immediately after birth, and usually the mother is not known to have dystrophia myotonica, the diagnosis is made when the baby is already being ventilated. We found it difficult to decide whether, and to what extent, we should continue treatment. The prognosis for both mental and physical handicap was discussed with the parents, but in each case they requested that every measure should be taken to keep the baby alive. The shock of hearing that both mother and baby have a serious disease must make a well-judged decision at such an emotional time extremely difficult for the parents.

Antenatal diagnosis could alleviate some of these problems. The gene for dystrophia myotonica is linked to the gene for secretor status and the latter can be determined in saliva and amniotic fluid. However this linkage is only helpful in antenatal diagnosis in about 15% of couples (Schrott *et al.*, 1973).

Until a better technique for antenatal diagnosis becomes available, the only reasonable approach would seem to be to attempt to identify all affected members of families with dystrophia myotonica and to offer genetic advice if appropriate. Recognition of the neonatal form of dystrophia myotonica can lead to the identification of such families and to more timely genetic counselling.

We thank the doctors and nurses involved in the treatment of these patients, the parents and relatives of the babies who co-operated in the family studies, the audio-visual departments of Sophia Children's Hospital and Dijkzigt for the photographs, and Mrs M. de Bruijne for secretarial help.

References

- Aicardi, J., Conti, D., and Goutières, F. (1974). Les formes néonatales de la Dystrophie myotonique de Steinert. *Journal of the Neurological Sciences*, **22**, 149–164.
- Bell, D. B., and Smith, D. W. (1972). Myotonic dystrophy in the neonate. *Journal of Pediatrics*, **81**, 83–86.
- Bossen, E. H., Shelburne, J. D., and Verkauf, B. S. (1974). Respiratory muscle involvement in infantile myotonic dystrophy. *Archives of Pathology*, **97**, 250–252.
- Dubowitz, V. (1969). *The Floppy Infant*. Clinics in Developmental Medicine No. 31. Heinemann: London.
- Dunn, L. J., and Dierker, L. J. (1973). Recurrent hydramnios in association with myotonia dystrophica. *Obstetrics and Gynecology*, **42**, 104–106.
- Dyken, P. R., and Harper, P. S. (1973). Congenital dystrophia myotonica. *Neurology*, **23**, 465–473.
- Harper, P. S. (1975). Congenital myotonic dystrophy in Britain. I. Clinical aspects. *Archives of Disease in Childhood*, **50**, 505–513.
- Harper, P. S., and Dyken, P. R. (1972). Early-onset dystrophia myotonica. Evidence supporting a maternal environmental factor. *Lancet*, **2**, 53–55.
- L'Hirondel, J., Guihard, J., Velot-Lerou, A., and Orange, Ch. (1970). La Maladie de Steinert Néonatale. *Semaine des hôpitaux de Paris*, **46**, 1867–1874.
- Messer, J., Brochard, A., Willard, D., and Jesel, M. (1973). Forme néonatale de la maladie de Steinert. *Acta paediatrica Belgica*, **27**, 263–272.
- Sarnat, H. B., O'Connor, T., and Byrne, P. A. (1976). Clinical effects of myotonic dystrophy on pregnancy and the neonate. *Archives of Neurology*, **33**, 459–465.
- Sarnat, H. B., and Silbert, S. W. (1976). Maturation arrest of fetal muscle in neonatal myotonic dystrophy. *Archives of Neurology*, **33**, 466–474.
- Schrott, H. G., Karp, L., and Omenn, G. S. (1973). Prenatal prediction in myotonic dystrophy: guidelines for genetic counselling. *Clinical Genetics*, **4**, 38–45.
- Simpson, K. (1975). Neonatal respiratory failure due to myotonic dystrophy. *Archives of Disease in Childhood*, **50**, 569–571.
- Stern, L. Z., Cross, H. E., and Crebo, A. R. (1978). Abnormal iris vasculature in myotonic dystrophy. *Archives of Neurology*, **35**, 224–227.
- Swift, T. R., Ignacio, O. J., and Dyken, P. R. (1975). Neonatal dystrophia myotonica. Electrophysiologic studies. *American Journal of Diseases of Children*, **129**, 734–737.
- van der Steeg, H. J., Gerards, L. J., and Willemse, J. (1977). Zwangerschap en bevalling bij een patiënte met dystrophia myotonica of de ziekte van Curschmann-Steinert; symptomatologie bij de pasgeborenen. *Nederlandsch tijdschrift voor geneeskunde*, **121**, 1879–1883.
- Vanier, T. M. (1960). Dystrophia myotonica in childhood. *British Medical Journal*, **2**, 1284–1288.

Correspondence to Dr R. G. Pearse, Sophia Children's Hospital and Neonatal Unit, Gordelweg 160, Rotterdam, The Netherlands.

Received 15 August 1978



Neonatal form of dystrophia myotonica. Five cases in preterm babies and a review of earlier reports.

R G Pearse and C J Höweler

Arch Dis Child 1979 54: 331-338
doi: 10.1136/adc.54.5.331

Updated information and services can be found at:
<http://adc.bmj.com/content/54/5/331>

Email alerting service

Receive free email alerts when new articles cite this article. Sign up in the box at the top right corner of the online article.

Notes

To request permissions go to:
<http://group.bmj.com/group/rights-licensing/permissions>

To order reprints go to:
<http://journals.bmj.com/cgi/reprintform>

To subscribe to BMJ go to:
<http://group.bmj.com/subscribe/>