

Technique for Use of Stainless-Steel Crowns in Primary Molars

by Joel Berg, DDS, MS & Jenn-Yih (Simon) Lin, DDS, MS

Abstract

This course will guide the clinician through the steps involved in successful placement of the stainless-steel crown. The stainless-steel crown can be easily placed by following the step-by-step approach outlined in this article. When placed properly and with good case selection, the stainless-steel crown should remain in place until the natural exfoliation of the primary molar.

Educational Objectives

After reviewing this program, participants will be able to:

1. identify the need for stainless-steel crowns in primary molars.
2. describe the steps involved in tooth preparation for primary molar stainless-steel crowns.
3. describe how to fit a stainless-steel crown into place on the prepared primary molar.
4. describe how to contour a stainless-steel crown when it is too wide mesio-distally.
5. describe how to properly cement a stainless-steel crown onto a primary molar.

This print or PDF course is a written self-instructional article with adjunct images and is designated for 1.5 hours of CE credit by Farran Media. Participants will receive verification shortly after Farran Media receives the completed post-test. See instructions on page 87.

AGD Code: 430



Approved PACE Program Provider
FAGD/MAGD Credit
Approval does not imply acceptance
by a state or provincial board of
dentistry or AGD endorsement.
1/1/2013 to 12/31/2015
Provider ID#304396

ADA C.E.R.P.® Continuing Education
Recognition Program

Farran Media is an ADA CERP Recognized provider. ADA CERP is a service of the American Dental Association to assist dental professionals in identifying quality providers of continuing dental education. ADA CERP does not approve or endorse individual courses or instructors, nor does it imply acceptance of credit hours by boards of dentistry.

continued on page 82

The stainless-steel crown (SSC) is one of the most important procedures in pediatric restorative dentistry. Stainless-steel crowns cover and protect the entire tooth and are very durable (Fig. 1). They also are very difficult to dislodge if placed properly, with excellent adaptation to the tooth.

They represent the preferred therapy for primary molar teeth after pulpotomy.

The stainless-steel crown is readily retained (often for the lifespan of the primary molar), because it fits over the contour of the buccal, lingual, mesial and distal surfaces of the tooth (Fig. 2). This “snap-on” feature of stainless-steel crowns causes retention of adapted stainless-steel crowns. This is obviously distinctly different from the way in which precision laboratory-fabricated cast restorations are placed in permanent teeth, after parallel preparation of the tooth and avoidance of any undercuts during tooth preparation.

The pre-cut, pre-contoured and pre-cripped stainless-steel crown is intended to fit over the cervix of the crown preparation with the same “snap-on” effect as the older generation, non-contoured crowns, but without all the trimming/reduction and contouring procedures. Additional crimping can also be done on the pre-contoured crowns (Fig. 3) to further improve the mechanical retention. It is desirable to avoid as many of the cutting and crimping steps as possible in order to save time during the procedure. This was the reason for the development of the pre-contoured crowns. The mechanical snap-on retention feature is important, although the degree of importance is changing with the advent of modern cements. During the era when zinc phosphate or zinc-oxide/eugenol cements were the primary cements of choice for stainless-steel crowns, the cement was mainly present to fill the void between the crown and the tooth.

Mechanical retention was the main force holding the crown in place. However, with modern cements, such as glass ionomer cements, there is chemical adherence to the tooth structure and mechanical adherence to the stainless-steel crown. This makes mechanical retention still desirable but not necessarily as critical. The marginal seal of the combination of a well-fitting crown and the cement interface is critical however.

Pre-contoured stainless-steel crowns make the practice of dentistry for children much easier by saving significant time. If a patient has lost space around the tooth to be crowned, the pre-contouring (with natural contours) can mean the mesial and distal surfaces of the crown are too bulbous to be fitted down on the tooth. Sometimes it is necessary to remove additional tooth structure from the mesial and distal surfaces of an adjacent primary tooth to create enough mesio-distal space for the crown to be placed, if squeezing the crown to reduce the mesio-distal width is not effective (Fig. 4). This can be easily accomplished with Howe pliers which exert a slight squeeze on the SSC while holding it on the mesial and distal aspects. When two SSC are prepared adjacent to one another, interproximal preparation must be made on each to the same extent as if there were only one of them prepared.

Rubber dam isolation for SSC procedures is strongly recommended. The entire procedure is typically accomplished with the rubber dam in position; including crown preparation, crown try-in and cementation.

There are at least two situations when one might want to remove the rubber dam prior to final placement of the crown. These involve cases where the opposing occlusion might interfere with crown placement and where the rubber dam clamp interferes with crown placement. This latter scenario often occurs when preparing a second primary molar for a SSC prior



Fig. 1

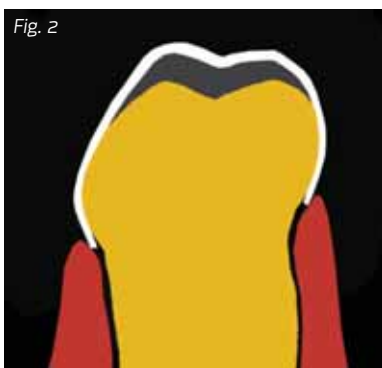

Fig. 2



Fig. 3

Fig. 1: Pre-contoured and pre-cripped stainless-steel crown (Pedo Crown, Hu-Friedy, Chicago, Illinois)

Fig. 2: Drawing of stainless-steel crown showing “minimalistic” tooth preparation

Fig. 3: Additional crimping can also be done on the pre-contoured crowns to further improve the mechanical retention.

Fig. 4: If a patient has lost space around the tooth to be crowned, the pre-contouring can mean the mesial and distal surfaces of the crown are too bulbous to be fitted down on the tooth.

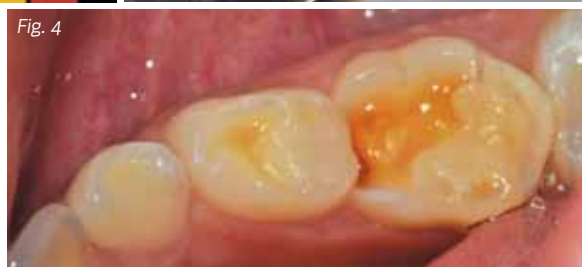

Fig. 4

to the eruption of the permanent first molar, and therefore where the rubber dam clamp must be placed on the second primary molar.

Once the rubber dam is placed after local anesthesia is obtained, tooth preparation can begin. There are three basic steps to tooth preparation for SSCs – (1) occlusal reduction, (2) buccal and lingual reduction/beveling, and (3) proximal reduction. Wedges can be placed between the teeth during the tooth reduction phase of the stainless-steel crown preparation (Fig. 5) so that cutting is done into the wedges rather than in the interproximal soft tissue. A carbide bur or a diamond bur can be used for preparation. Some pediatric dentists use diamond burs to speed up the procedure to minimize the likelihood of behavior management problems by extending beyond the desirable time of cooperation for the child. Tapered burs are good choices for

interproximal tooth reduction. Using one type of bur for the entire operation reduces the time required by eliminating the steps involved in changing burs. Some prefer to use a carbide bur for the entire crown preparation procedure, where changing burs is unnecessary. Regardless, using time efficiently is very important to exhibit good behavior management in providing dental care to children.

Depth cuts can be used as a gauge to help establish the depth of the occlusal reduction (Fig. 6).

As has been mentioned, occlusal reduction can be done by generally following the external contours of the tooth (Fig. 7). However, if a pulpotomy is planned, simple reduction of the occlusal aspect straight across by removing 1-1.5mm of tooth structure should be accomplished. A large football-shaped bur or round bur is good for accomplishing this step rapidly and effectively.

The next step involves the buccal and lingual reduction/beveling elements of the preparation (Fig. 8). It is best to only slightly reduce the cervical bulges of *some* teeth just above the gingival tissue. Generally, most experienced practitioners only prepare the occlusal half of the buccal and lingual surfaces, above the bulges on the gingival aspect of these surfaces. This reduction is also generally limited to a 45-degree angled bevel from the reduced occlusal surface onto the occlusal half of the buccal and lingual surfaces (Fig. 2). Ordinarily it is not necessary to reduce tooth structure subgingivally during the buccal reduction process. This is true for lingual reduction as well. However, in the case of first primary molars, the buccal bulges often are very prominent, it is sometimes necessary to remove the buccal bulge in order to allow the preformed crown to fit over the buccal prominence (Fig. 9). The preparation will be somewhat below the height of the free gingiva in these cases.

Beyond coping with the buccal bulges of some primary molars, various authors have suggested different approaches to the buccal and lingual reduction/beveling step of SSC preparation. We will review the various approaches. The buccal and lingual reduction/beveling steps are started after the occlusal

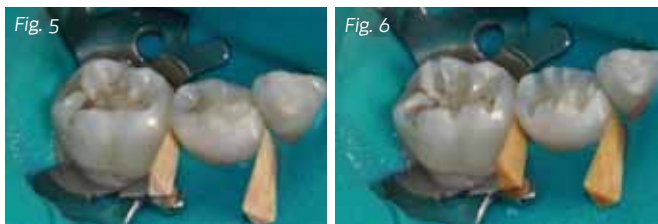


Fig. 5: Rubber dam isolation with wedges before tooth preparation

Fig. 6: Depth cuts used to gauge preparation depth

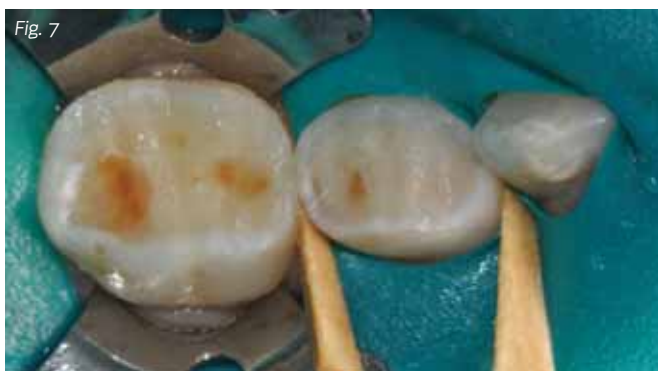

Fig. 7: Occlusal reduction generally follows external tooth contours

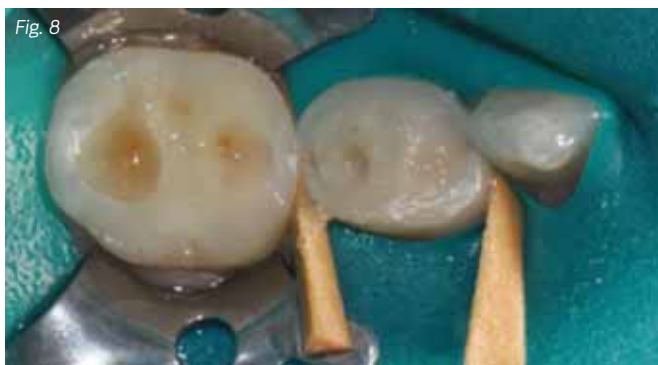

Fig. 8: Buccal and lingual beveling followed by complete removal of caries was performed with a low-speed round bur.

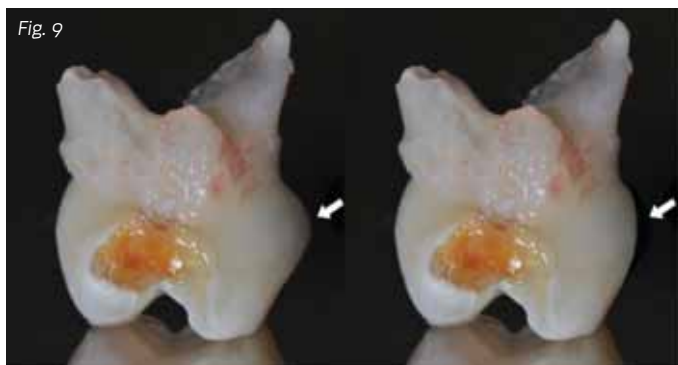


Fig. 9: Mesial view of a mandibular right first primary molar and clearly demonstrates the presence of the large buccal bulge (left). Some reduction of the bulge area often is necessary (right).

continued on page 84

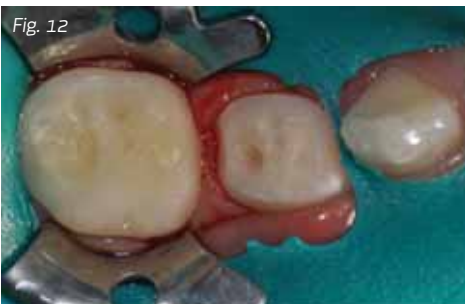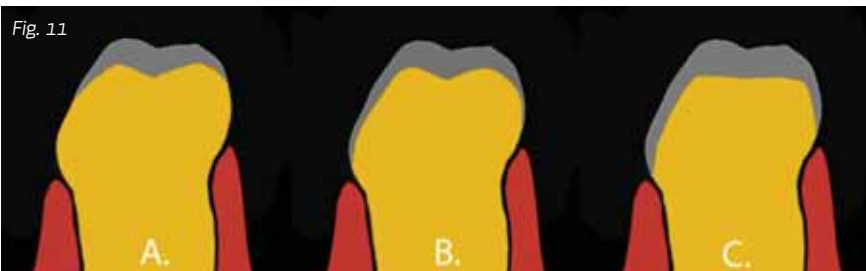

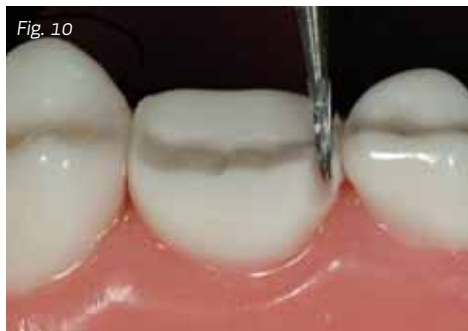
Fig. 10: The bur needs to be angled so as not to damage the adjacent teeth.

Fig. 11: Three approaches to the buccal and lingual reduction/beveling step

Fig. 12: Final preparation before fitting the stainless-steel crowns; all line and point angles were rounded.

reduction step. As mentioned earlier, the occlusal reduction step involves the reduction of the occlusal surface by approximately 1.0-1.5mm (as displayed in the diagram). Some authors recommend roughly following the occlusal surface morphology. Other authors indicate that a flat occlusal surface preparation is preferred so that the procedure can be accomplished more rapidly. We believe that either approach is acceptable, although if the latter approach is taken, care must be taken to avoid exposing the pulp unnecessarily. The important consideration is to make sure that occlusal reduction is extended enough so that the crown will not be in hyper-occlusion once it is placed.

As noted, routine reduction of the entire buccal or lingual surface is not recommended, but rather reduction should only involve removal of very prominent buccal bulges and the beveling step (in rare cases). The advantage of this technique is that greater natural mechanical retention might be obtained from the buccal and lingual surfaces since no reduction occurs on most of those surfaces.

Generally, interproximal slices are made after the occlusal and buccal-lingual reduction steps, since the interproximal reduction phase is easier after reduction of the other surfaces. It is important not to damage the interproximal surfaces of adjacent teeth, particularly if an adjacent permanent tooth exists. Consequently, the bur needs to be angled so as not to damage the adjacent teeth. Figure 10 demonstrates the approximate bur angulation during mesio-interproximal reduction of the second primary molar. One of the most common errors in preparing teeth for stainless-steel crowns is to leave an interproximal ledge, as also shown in figure 10 (where the preparation is not yet complete). A preparation with a ledge will not allow the stainless-steel crown to seat completely, because the SSC will get caught on the ledge. An explorer or bur can be used to check for ledges by moving up and down the proximal surface to verify a smooth interface that is ledge-free. If a ledge is present, it needs to be removed with a bur.

All lines, points and angles should be rounded. The most important advantage of this approach is that the restored tooth

will have an overall size and morphology that is closer to that of the original tooth. It is also possible that less tissue blanching will result when the buccal and lingual surfaces are reduced by the thickness of the stainless crown and the restored tooth will better simulate the original morphology of the tooth, but this can lead to less retention and take more time and expertise in preparation.

We have reviewed three approaches to the buccal and lingual reduction/beveling step (Fig. 11). They are as follows:

- Beveling the buccal and lingual surfaces, but not reducing the overall surfaces.
- Beveling the buccal and lingual surfaces and slightly reducing the buccal and lingual surfaces (to the approximate thickness of a stainless-steel crown).
- Reducing the occlusal, buccal and lingual surfaces significantly, with a resulting trapezoidal-shaped preparation.

The determination of the approach might be made based on the ability to be consistent in methodology regardless of the majority of circumstances. In this way, dentists along with staff will gain familiarity with whatever technique is expected and be able to select and fit stainless-steel crowns more efficiently.

Our experience with SSCs is that they are highly durable, very well-retained and well-tolerated using each of the approaches described. Especially helpful is that all the preparation styles preserve the subgingival area of the buccal and lingual surfaces so that mechanical retention can be obtained. Rounding all line and point angles is necessary before selection of the correct crown size in the crown preparation process (Fig. 12). Trial and error is the most practical approach at first. Experienced clinicians find they often can estimate the correct crown size simply by viewing the preparation. However, the trial and error method is used until the appropriate size is found. A gauge can be used to measure the mesio-distal space, which is then used to determine the correct crown size.

Even with the newer crowns (Fig. 13), some trimming and adaptation occasionally will be necessary. For example, a necessary adjustment might occur where a size 4 crown is too small and a size 5 is too big (crowns are available in integer sizes from 2-7). A size 4½ would be perfect, but no such crown exists. A size 5 can be used in these cases by crimping to make the crown tighter or the tooth circumference can be decreased by trimming the periphery of the tooth to make the tooth fit the smaller size 4 crown, or by squeezing the larger-sized crown as described.

SSCs might cause slight tissue irritation and are not as aesthetically desirable as resin composite, for example. The amount of tissue irritation generally is not significant in healthy children. However, parents should be instructed to make sure that the teeth are carefully brushed around the crowns. When problems arise with crowns, the cause is usually poor hygiene. Cement caught in the interproximal area is another potential problem. SSC margins should be placed right at or slightly below the height of the free gingiva. Fortunately, the advent of new preformed crowns has made most trimming unnecessary. SSCs might be cemented with a variety of glass ionomer cements depending on the preference of the clinician. Most commonly, traditional (pure) glass ionomer cement is used, but some clinicians prefer resin-modified glass ionomer cement. If resin-modified glass ionomer cement is used, one should be aware that the resin portion might not cure properly unless it is of the “tri-cure” variety, where there exists a self-curing mechanism of the resin components. Regardless of cement choice, after placement it is necessary to remove the excess cement carefully after the cement is fully set. It is particularly important to go between the teeth with a string of knotted floss to remove excess cement interproximally. It is best to gently use the knotted floss in the interproximal area and saw bucco-lingually, which will remove excess cement without dislodging the crown. Lifting up on the floss might dislodge the crown (glass ionomer cement is not fully set for 24 hours) and should be avoided. The next step is to go around the teeth with an explorer to check for excess cement. It is also important to check the bite, since the rubber dam probably has been used throughout the procedure. The crowns need to be checked with the rubber dam off, especially when the cement is not yet set so adjustments can be made if necessary. It is important to check the occlusion by having the patients bite on the newly cemented crowns. ■

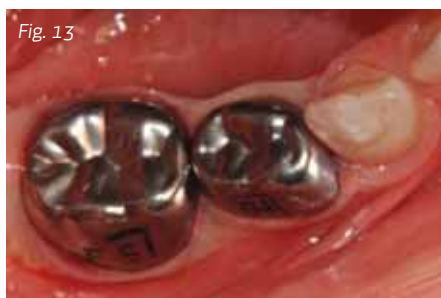

Fig. 13: Stainless-steel crowns after cementation with traditional glass ionomer cement (Ketac-Cem 3M ESPE, St. Paul, Minnesota)

3. Yilmaz Y, Simsek S, Dalmis A, Gurbuz T, Kocogullari ME. Evaluation of stainless steel crowns cemented with glass-ionomer and resin-modified glass-ionomer luting cements. *Am J Dent.* 2006 Apr;19(2):106-10.
4. Seale NS. The use of stainless steel crowns. *Pediatr Dent.* 2002 Sep-Oct;24(5):501-5. Review.
5. Randall RC. Preformed metal crowns for primary and permanent molar teeth: review of the literature. *Pediatr Dent.* 2002 Sep-Oct;24(5):489-500. Review.
6. Guelmann M, Mjör IA. Materials and techniques for restoration of primary molars by pediatric dentists in Florida. *Pediatr Dent.* 2002 Jul-Aug;24(4):326-31.
7. Croll TP. Preformed posterior stainless steel crowns: an update. *Compend Contin Educ Dent.* 1999 Feb;20(2):89-92, 94-6, 98-100 passim; quiz 106. Review.
8. Vincikier F, Gizani S, Declerck D. Comprehensive dental care for children with rampant caries under general anaesthesia. *Int J Paediatr Dent.* 2001 Jan;11(1):25-32.
9. Soxman JA. Stainless steel crown and pulpotomy: procedure and technique for primary molars. *Gen Dent.* 2000 May-Jun;48(3):294-7.
10. Einwag J, Dünninger P. Stainless steel crown versus multisurface amalgam restorations: an 8-year longitudinal clinical study. *Quintessence Int.* 1996 May;27(5):321-3.
11. Kilpatrick NM. Durability of restorations in primary molars. *J Dent.* 1993 Apr;21(2):67-73.

Author's Bio



Dr. Joel Berg became Dean of the University of Washington School of Dentistry in August 2012. Prior to that, he was the chair of pediatric dentistry, dental director for Seattle Children's and associate dean for Hospital Affairs at the School of Dentistry. Dean Berg obtained his DDS, a certificate in pediatric dentistry and an MS in oral biology from the University of Iowa. Before joining the UW, he also served on dental faculty at the University of Pennsylvania and the University of Texas. He is currently president of the American Academy of Pediatric Dentistry and was recently chosen to be a national spokesman for a public service advertising campaign to promote dental health.

Berg has authored or co-authored more than 100 abstracts, articles and chapters, and is co-editor of a textbook on early childhood oral health. His current research includes innovative new technologies for early detection of caries, one of his principal research and academic interests. He is a fellow of the American College of Dentists and International College of Dentists, as well as a board director of the American Academy of Esthetic Dentistry. In 2011, he was named the eighth Washington Dental Service Foundation Distinguished Professor for Dentistry.

Jenn-Yih (Simon) Lin, DDS, MS, is a Clinical Assistant Professor of Pediatric Dentistry at the University of Washington School of Dentistry. He has been the Predoctoral Program Director since 2007 and is a favorite with the dental students. Dr. Lin received his DDS in 1995 from National Yang-Ming University in Taipei, Taiwan. In 2002, he received his certificate in Pediatric Dentistry and a Master of Science degree from Tufts University School of Dental Medicine, Boston. He spent a year conducting molecular genetic research on Oligodontia at Harvard Medical School.



Dr. Lin is enthusiastic about integrating computing technology into effective instructional materials. He has implemented podcasting and an audience response system to facilitate students' learning. He is currently developing an app for mobile devices to improve students' learning experience in pediatric dentistry.

Disclaimer: The authors declare that neither they nor any member of their families have a financial arrangement or affiliation with any corporate organization offering financial support or grant monies for this continuing education program. Although commercially available products are discussed, no financial arrangements exist between the manufacturers and the authors.

1. Attari N, Roberts JF. Restoration of primary teeth with crowns: a systematic review of the literature. *Eur Arch Paediatr Dent.* 2006 Jun;7(2):58-62; discussion 63. Review.
2. Hutcheson C, Seale NS, McWhorter A, Kerins C, Wright J. Multi-surface composite vs stainless steel crown restorations after mineral trioxide aggregate pulpotomy: a randomized controlled trial. *Pediatr Dent.* 2012 Nov-Dec;34(7):460-7.

Post-test

Claim Your CE Credits

Answer the test in the Continuing Education Answer Sheet and submit it by mail or fax with a processing fee of \$36. You can also answer the post-test questions online at www.dentaltown.com/onlinece. We invite you to view all of our CE courses online by going to www.dentaltown.com/onlinece and clicking the View All Courses button. Please note: If you are not already registered on www.dentaltown.com, you will be prompted to do so. Registration is fast, easy and of course, free.

1. In how many sizes are SSC typically available?
 - a. Three
 - b. Five
 - c. Six
 - d. Seven
2. Which of the following is a common problem in preparing a primary molar for a SSC?
 - a. Leaving an undercut
 - b. Not completely removing buccal bulge
 - c. Not identifying the pulp
 - d. Creating a proximal ledge during preparation
3. What cement is most commonly used to cement SSC in primary molars?
 - a. ZOE
 - b. Resin
 - c. Glass ionomer
 - d. Resin-modified glass ionomer
4. Which of the following is true regarding pre-contoured SSC?
 - a. They always need to be crimped.
 - b. The buccal bulge needs to be eliminated.
 - c. They often are far too large for the tooth.
 - d. They will snap over the buccal bulge.
5. Rubber dam use for SSC preparation in children is:
 - a. rarely needed.
 - b. difficult to accomplish.
 - c. generally recommended.
 - d. contraindicated.
6. When cementing a SSC onto a primary molar:
 - a. the rubber dam might need to be removed.
 - b. the excess cement should be removed before it is set.
 - c. there is no concern about excess cement.
 - d. never use floss to remove excess cement.
7. What type of pliers can be used to reduce the mesio-distal size of a SSC?
 - a. Howe
 - b. Three-pronged
 - c. Bird-beak
 - d. Cotton pliers
8. Which of the following is a good method to make the right occlusal depth for an SSC preparation?
 - a. Use depth cuts.
 - b. Use a football diamond.
 - c. Never use a diamond bur.
 - d. Do the occlusal preparation last.
9. Which of the following cements bonds chemically to teeth?
 - a. ZOE
 - b. Resin
 - c. Glass ionomer
 - d. Zinc phosphate
10. Which of the following is *not* true regarding SSC for primary molars?
 - a. They often last the life of the primary tooth.
 - b. They are difficult to place.
 - c. They always need to be cut with scissors.
 - d. They always need to be cemented.

Legal Disclaimer: The CE provider uses reasonable care in selecting and providing content that is accurate. The CE provider, however, does not independently verify the content or materials. The CE provider does not represent that the instructional materials are error-free or that the content or materials are comprehensive. Any opinions expressed in the materials are those of the author of the materials and not the CE provider. Completing one or more continuing education courses does not provide sufficient information to qualify participant as an expert in the field related to the course topic or in any specific technique or procedure. The instructional materials are intended to supplement, but are not a substitute for, the knowledge, expertise, skill and judgment of a trained healthcare professional. You may be contacted by the sponsor of this course.

Licensure: Continuing education credits issued for completion of online CE courses may not apply toward license renewal in all licensing jurisdictions. It is the responsibility of each registrant to verify the CE requirements of his/her licensing or regulatory agency.

Continuing Education Answer Sheet

Instructions: To receive credit, complete the answer sheet and mail it, along with a check or credit card payment of \$36 to: Dentaltown.com, Inc., 9633 S. 48th Street, Suite 200, Phoenix, AZ 85044. You may also fax this form to 480-598-3450 or answer the post-test questions online at www.dentaltown.com/onlinece. This written self-instructional program is designated for 1.5 hours of CE credit by Farran Media. You will need a minimum score of 70 percent to receive your credits. Participants only pay if they wish to receive CE credits, thus no refunds are available. **Please print clearly. This course is available to be taken for credit June 1, 2013 through its expiration on June 1, 2016. Your certificate will be e-mailed to you within 3-4 weeks.**

Technique for Use of Stainless-Steel Crowns in Primary Molars by Joel Berg, DDS, MS & Jenn-Yih (Simon) Lin, DDS, MS

License Number _____

AGD# _____

Name _____

Address _____

City _____ State _____ ZIP _____

Daytime phone _____

E-mail (required for certificate) _____

☐ Check (payable to Dentaltown.com, Inc.)

☐ Credit Card (please complete the information below and sign; we accept Visa, MasterCard and American Express.)

Card Number _____

Expiration Date – Month / Year _____ / _____

Signature _____ Date _____

Program Evaluation (required)

Please evaluate this program by circling the corresponding numbers: (5 = Strongly Agree to 1 = Strongly Disagree)

1. Course administration was efficient and friendly	5	4	3	2	1
2. Course objectives were consistent with the course as advertised	5	4	3	2	1
3. COURSE OBJECTIVE #1 was adequately addressed and achieved	5	4	3	2	1
4. COURSE OBJECTIVE #2 was adequately addressed and achieved	5	4	3	2	1
5. COURSE OBJECTIVE #3 was adequately addressed and achieved	5	4	3	2	1
6. COURSE OBJECTIVE #4 was adequately addressed and achieved	5	4	3	2	1
7. COURSE OBJECTIVE #5 was adequately addressed and achieved	5	4	3	2	1
8. Course material was up-to-date, well-organized, and presented in sufficient depth	5	4	3	2	1
9. Instructor demonstrated a comprehensive knowledge of the subject	5	4	3	2	1
10. Instructor appeared to be interested and enthusiastic about the subject	5	4	3	2	1
11. Audio-visual materials used were relevant and of high quality	5	4	3	2	1
12. Handout materials enhanced course content	5	4	3	2	1
13. Overall, I would rate this course:	5	4	3	2	1
14. Overall, I would rate this instructor:	5	4	3	2	1
15. Overall, this course met my expectations	5	4	3	2	1

Comments (positive or negative): _____

For questions, contact Director of Continuing Education Howard Goldstein at hogo@dentaltown.com

CE Post-test

Please circle your answers.

- | | | | | |
|-----|---|---|---|---|
| 1. | a | b | c | d |
| 2. | a | b | c | d |
| 3. | a | b | c | d |
| 4. | a | b | c | d |
| 5. | a | b | c | d |
| 6. | a | b | c | d |
| 7. | a | b | c | d |
| 8. | a | b | c | d |
| 9. | a | b | c | d |
| 10. | a | b | c | d |